



Contents lists available at ScienceDirect

Asian Pacific Journal of Tropical Disease

journal homepage: www.elsevier.com/locate/apjtd

Document heading doi:10.1016/S2222-1808(11)60059-5

Upper lobe pulmonary edema and dry gangrene in scorpion sting

Stalin Viswanathan*, Vivekanandan Muthu, Nayyar Iqbal

Department of Internal Medicine, Pondicherry Institute of Medical Sciences, Pondicherry 605014

ARTICLE INFO

Article history:

Received 27 April 2011
 Received in revised form 8 May 2011
 Accepted 24 May 2011
 Available online 1 June 2011

Keywords:

Scorpion envenomation
 Asymmetrical pulmonary edema
 Right upper lobe edema
 Peripheral gangrene

ABSTRACT

A 17 year old student admitted to our hospital following a red scorpion sting had pulmonary edema and hypotension. Chest radiography revealed asymmetrical upper lobe pulmonary edema with air bronchogram. Due to high counts, antibiotics were initiated. Chest radiograph indicated that the chest radiography abnormalities were improved within 36 hours. Thirty hours after admission he developed discoloration of left foot which was managed conservatively with heparin and warfarin. His inotropes were gradually tapered and stopped 78 hours after admission. Echocardiography repeated on the sixth day of his admission was normal. He was discharged on pentoxifylline, warfarin and tramadol since there was no surgical intervention possible due to poor demarcation.

1. Introduction

Scorpion stings arising from thirty odd species among 1 500 cause human envenomation in the tropics[1]. Among them, *Mesobuthus tamulus* is the most common cause of severe envenomation in India. Asymmetrical diffuse pulmonary edema due to scorpion envenoming has been described once earlier in a 12 year old boy[2]. We report an asymmetrical albeit a predominantly right upper lobe pulmonary edema mimicking a consolidation in a 17 year old male. The boy also developed dry gangrene of his left foot that was treated conservatively.

2. Case report

This boy was stung by a red scorpion on his left wrist following which he had pain and numbness of the forearm. He was immediately seen at a nursing home and found to be hypotensive. Diclofenac, chlorpheniramine and dobutamine had been administered. Within 30 minutes, the boy had become dyspneic at rest and was shifted to our hospital. During transit, he had vomited and complained of chest

pain. On admission, his peripheries were cold and he was frothing at the mouth, tachypneic (40/minute) and unable to maintain saturation on a Venturi mask with FiO₂ of 60%. Pulse and blood pressure were 130/min and 80/40 mm Hg, respectively. Chest auscultation revealed crackles in all lung fields. He was intubated on arrival, placed on SIMV+ pressure support mode ventilation with FiO₂ of 100% and infused dopamine, dobutamine, and frusemide besides nasogastric administration of 0.5 mg prazosin every six hours. A left femoral arterial line was placed after his admission to ICU.

His investigations were as follows: total counts 25 400/mm³, with 93% neutrophilia; prothrombin time prolongation of 3.6 seconds, activated partial thromboplastin time (aPTT) prolongation of 4.3 seconds, creatine kinase-MB fraction 204 units/L, Trop I positivity, normal renal and liver function tests, mild global hypokinesia with 40% ejection fraction on echocardiography, asymmetrical pulmonary edema with predominant right upper lobe involvement and air bronchogram on chest radiography (CXR). In view of CXR abnormalities (Figure 1) and elevated counts he was initiated on ceftazidime and levofloxacin. On the second day his CXR abnormalities were improved (Figure 2). Thirty hours after admission the patient indicated the pain was in his left leg. Dorsalis pedis and posterior tibial arterial pulses were absent, the foot was cold and all the toes were discolored. Suspecting embolic peripheral arterial disease in the

*Corresponding author: Stalin Viswanathan, Department of Internal Medicine, Pondicherry Institute of Medical Sciences, Pondicherry 605014, India.
 Tel: 91-0413-3051111
 E-mail: stalinviswanathan@gmail.com

presence of left-ventricular dysfunction, heparin infusion with aPTT monitoring and warfarin were commenced, and the arterial line was removed. An arterial Doppler could not

be performed due to technical reasons. His inotropes were gradually tapered and stopped 78 hours after admission. Echocardiography repeated on the sixth day of his admission was normal. He was discharged on pentoxifylline, warfarin and tramadol since there was no surgical intervention possible due to poor demarcation.

3. Discussion

Scorpion venom causes an initial parasympathetic followed by sympathetic stimulation that leads to many of its common manifestations. The most common and best studied complications are cardiovascular. Hypertension, hypotension, electrocardiographic changes of myocardial ischemia, arrhythmias and pulmonary edema are well known. Pulmonary edema in scorpion envenoming involves two major factors. Firstly, an adrenergic stimulation caused left ventricular failure due to an acute increase in arterial blood pressure causing, and impaired ventricular filling due to sinus tachycardia. Secondly, a massive catecholamine release caused peripheral venous smooth muscle contraction leading to augmented venous return, and catecholamine mediated kinin/inflammatory cytokines or platelet activating factor release enhanced pulmonary vascular permeability^[3,4].

Chest radiograph patterns in pulmonary edema vary depending on whether pathophysiologically there is a hydrostatic pressure edema, a permeability edema with or without diffuse alveolar damage, or a mixture of both^[5]. Hydrostatic pressure edema has either an interstitial or a batwing pattern. Asymmetrical hydrostatic edema occurs due to preexisting chronic obstructive lung disease or fibrosis, neither of which was seen in our patient, a previously healthy adolescent. Permeability edema is generally peripheral in distribution, with a gravity gradient and without signs of cardiomegaly or Kerley B lines. Air bronchograms are more commonly observed in permeability edema as in our patient.

Unilateral pulmonary edema is a rare finding. Asymmetrical pulmonary edema is either due to ipsilateral lung or contralateral lung edema. In the first, edema occurs on the side of the lung pathology, for example, aspiration. In the second, a pathology on one side, for example pulmonary embolism, causes pulmonary edema in the contralateral lung^[6]. Cardiogenic causes like mitral regurgitation, paravalvular leakage, mitral valvular involvement by malignancy, left atrial myxoma, pulmonary venous compression, unilateral venoocclusive disease and non-cardiogenic factors like the dependent lung in lateral decubitus position, aspiration pneumonitis, pulmonary embolism, injury due to surgery, trauma or lung re-expansion can cause such a finding^[6–8]. Two cases of unilateral pulmonary edema due to scorpion envenomation have been reported^[2]. Right upper lobe edema has been

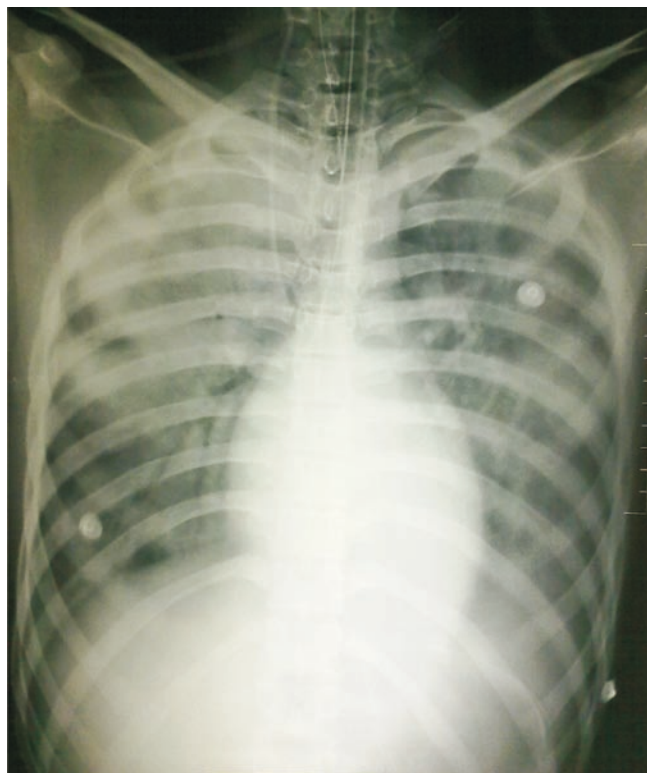

Figure 1. Chest radiograph on day 1 revealing asymmetrical right upper and mid zone alveolar infiltrates with air bronchograms.

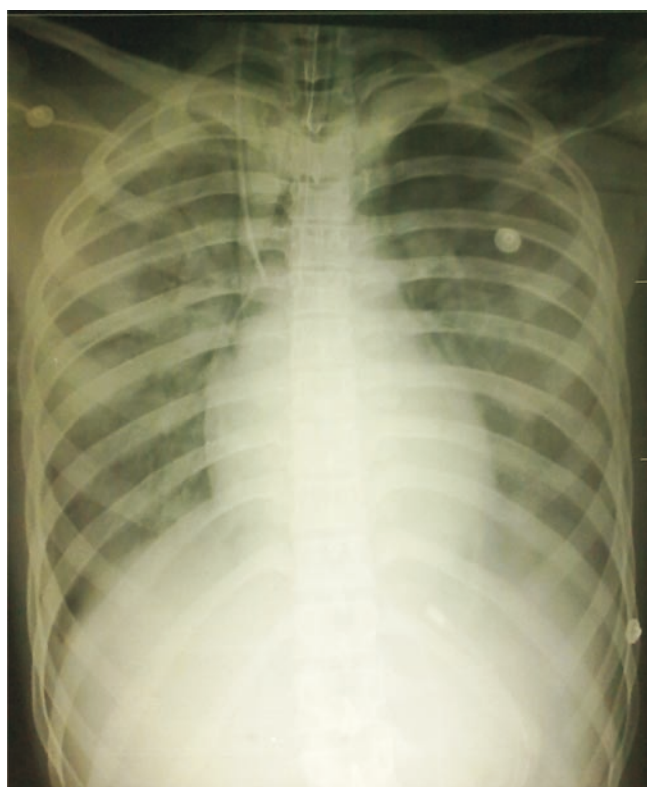


Figure 2. Chest radiograph on day 2 showing clearing of alveolar opacities.

most commonly reported due to mitral regurgitation^[6]. Right upper lobe pulmonary edema has been described in mitral regurgitation due to a preferential blood jet in the right superior pulmonary vein and due to focal consolidation in the right upper lobes^[9]. Though asymmetrical pulmonary edema has been described once in scorpion sting envenomation, a predominant right upper lobe involvement with air bronchograms is being reported for the first time^[2].

Dry gangrene following scorpion sting has been reported once, way back in 1948, in a 17 year old girl^[10]. She developed it at the site of sting (single finger) and it was hypothesized that either local application of potassium permanganate/starch poultice to the sting site or the direct action of the venom itself had caused the dry gangrene. Another case of gangrene (albeit wet) developing at the sting site has been described in one case by Chadha *et al.* The patient had developed a large necrotic area over the leg that required skin grafting^[12]. Our patient developed dry gangrene at a site different from the sting, on the second day. Vascular events, especially cerebrovascular, have been attributed to disseminated intravascular coagulation, focal vasculitis due to venom or an adrenergic stimulus related vasoconstriction causing reduced blood flow^[11–17]. Prothrombin time and aPTT were normal in our patient and hence fibrinogen and fibrinogen degradation products were not done. Arterial Doppler two weeks later at follow-up, revealed reduced to absent anterior tibial arterial blood flow. It was probably due to transient thrombosis or vasospasm related to the

arterial line placed during time of initial resuscitation and associated left ventricular dysfunction. His pain, local warmth and toe movements had improved with warfarin and heparin. At follow up two weeks later, his gangrene did not require regular pain relief medications (Figure 3).

Although pulmonary edema is a common finding in scorpion–sting envenomation, right upper lobe edema with air–bronchograms is an uncommon finding and may mimic a consolidation due to cough, breathlessness and elevated total counts. Peripheral arterial gangrene at a site unrelated to the sting is rare and its etiology is multifactorial.

Conflict of interest statement

We declare that we have no conflict of interest.

References

- [1] Chippaux JP, Goyffon M. Epidemiology of scorpionism: a global appraisal. *Acta Trop* 2008; **107**: 71–79.
- [2] Razi E, Malekanrad E. Asymmetric pulmonary edema after scorpion sting: a case report. *Rev Inst Med Trop Sao Paulo* 2008; **50**: 347–350.
- [3] Ismail M. The scorpion envenoming syndrome. *Toxicon* 1995; **33**: 825–858.
- [4] Bawaskar HS, Bawaskar PH. Efficacy and safety of scorpion antivenom plus prazosin compared with prazosin alone for venomous scorpion (*Mesobuthus tamulus*) sting: randomised open label clinical trial. *BMJ* 2011; **342**: e7136.
- [5] Gluecker T, Capasso P, Schnyder P, Gudinchet F, Schaller MD, Revelly JP, et al. Clinical and radiologic features of pulmonary edema. *Radiographics* 1999; **19**: 1507–1531.
- [6] Ono A, Okada F, Ando Y, Maeda T, Nagai H, Kadota J, et al. Localised right upper-lobe pulmonary oedema caused by extension of giant cell carcinoma to the mitral valve. *Br J Radiol* 2011; **84**: e4–e6.
- [7] Chong S, Choi EJ, Youn I, Choe JW, Choi JC, Seo JS. Localized pulmonary edema in the right upper lobe associated with left atrial myxoma. *Clin Imaging* 2009; **33**: 398–401.
- [8] Denis J, Hoffer E. Unilateral pulmonary edema caused by paravalvular leakage recognized by bedside transesophageal echocardiography. *Acta Anaesthesiol Belg* 2006; **57**: 153–155.
- [9] Young AL, Langston CS, Schiffman RL, Shortsleeve MJ. Mitral valve regurgitation causing right upper lobe pulmonary edema. *Tex Heart Inst J* 2001; **28**: 53–56.
- [10] Ansari MY. Gangrene after scorpion sting. *Br Med J* 1948; **2**: 388.
- [11] Gadwalkar SR, Bushan S, Pramod K, Gouda C, Kumar PM. Bilateral cerebellar infarction: a rare complication of scorpion sting. *J Assoc Physicians India* 2006; **54**: 581–583.
- [12] Chadha JS, Leviav A. Hemolysis, renal failure, and local necrosis following scorpion sting. *JAMA* 1979; **241**: 1038.

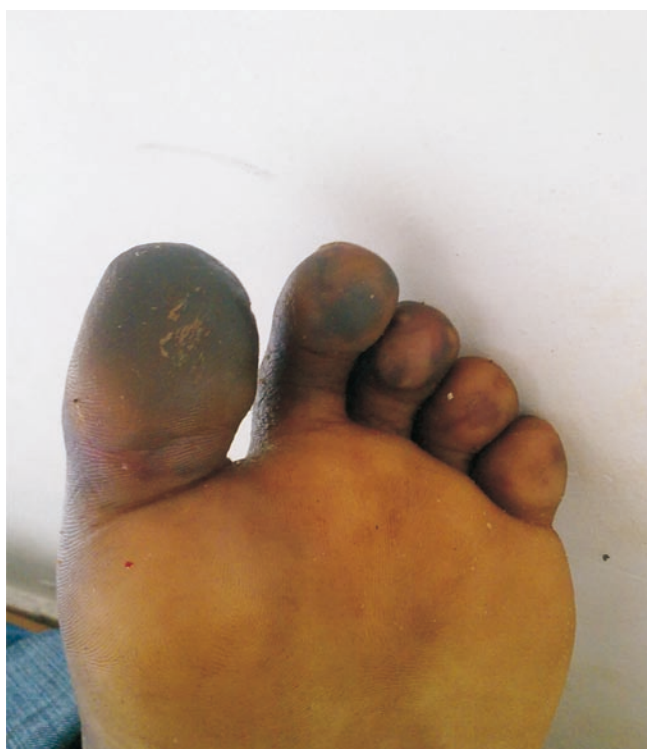

Figure 3. Left foot of patient at follow-up 2 weeks after discharge revealing poorly demarcated dry gangrene.