



Contents lists available at ScienceDirect

Asian Pacific Journal of Tropical Disease

journal homepage: www.elsevier.com/locate/apjtd

Document heading doi:10.1016/S2222-1808(11)60029-7

A longitudinal study of neurocysticercosis through CT scan of the brain

Abhiram Chakraborty¹, Saikat Panja², Indranil Bhattacharjee³, Goutam Chandra³, Amiyakumar Hati^{1*}¹Calcutta School of Tropical Medicine, Kolkata, India, 700 073²West Bengal University of Technology, Kolkata, India, 700 064³Burdwan University, Burdwan, India, 713 104

ARTICLE INFO

Article history:

Received 5 May 2011

Received in revised form 27 May 2011

Accepted 10 July 2011

Available online 28 September 2011

Keywords:

Neurocysticercosis

Diagnosis

CT scan

Longitudinal study

Sensitivity

Specificity

Cysticercosis

Parasitic infection

MRI

Convulsion

Headache

Health concern

ABSTRACT

Objective: To find out the role of CT scan in the diagnosis of neurocysticercosis (NC) and also to get an idea of the nature and extent of this disease in a definite geographical ethnic location.

Methods: CT scan of the brain of altogether 4 762 persons residing in a congested area of central Kolkata, was performed between 2004 and 2010, in an imaging centre in central Kolkata (Calcutta), of whom 1 114 (23.39%) suspected patients were investigated for NC, having complaints of convulsion (472), headache (272), right sided weakness (98), loss of consciousness (84), left sided weakness (61), abnormal behavior (48), slurring of speech (34), difficulty with keeping balance (33) and dementia (12). **Results:** NC was detected in 45, 1, 0, 2, 1, 0, 0, 1 and 0, respectively consisting 4.48% (50/1 114) of the suspected cases varying from as low as 2 (in 2006) to as high as 23 (in 2005) in different years indicating this parasitic infection is perennial. The age of patients varied from 6 to 59 years of whom 28 (56%) were vegan. We were also able to detect 4 types of lesions *viz.* calcified lesions (14), small hypodense *i.e.* vesicle (12), bright central spot *i.e.* vesicular lesion with central spot (2) and ring enhancement (22). For 3 patients, further imaging investigation (MRI) was needed to confirm the diagnosis. We calculated the specificity and sensitivity of CT scan of brain diagnosing NC which was found to be 64% and 100%, respectively. **Conclusions:** Although, the sample may not be the representatives of the whole community, the findings suggest that cysticercosis is a significant but under-recognized public health concern in Kolkata.

1. Introduction

Neurocysticercosis (NC) is a well recognized global and common parasitic disease during these days^[1,2]. The common symptoms associated with NC are epilepsy^[3], loss of consciousness, headache, abnormal behavior^[4] *etc.* Patients with these symptoms are often referred to the imaging centre for diagnosis for NC through CT scan/MRI of the brain, as NC is an abnormality which is better diagnosed by the introduction of CT scan and MRI than any previous recognized radiological procedures^[5] in the brain. A study was planned to analyze CT scan of the brain of the patients sent for identifications in an imaging centre, suspected to be suffering from NC. The aims and objectives of this study were: 1) to find out the role of CT scan to diagnose NC cases in brain where no other laboratory tests were performed; 2) to calculate sensitivity and specificity of CT scan of the brain in diagnosing NC; 3) to get an idea of the nature and

extent of this disease in a definite geographical ethnic location; 4) to document different types of NC lesions in the brain.

2. Materials and methods

The study was conducted in Gautam Laboratories–Imaging and Research Centre, 7–Kalikrishna Tagore Street, Kolkata 700007, situated in Central Kolkata providing all super–specialty services in radiology and hematology. The study period extended from January 2004 to December 2010. CT scans of the brain of the patients were referred to this imaging centre by the local doctors, suspected to be suffering from NC. All details about each patient like name, age, sex, food habit *i.e.* vegan or non vegan, recent complaints, *etc.* were recorded. The lesions on the brain of the patients suffering from NC were analyzed. Sensitivity and specificity, regarding the diagnosis through a statistical model, were also studied.

3. Results

*Corresponding author: Dr. Amiya Kumar Hati, Former Professor and Head Department of Medical Entomology and Former Director, Calcutta School of Tropical Medicine, Residence: 8/1D, Neogipara Road, Kolkata–700 036, West Bengal, India.

Tel: +91–9432173465

E-mail: amiya_hati@rediffmail.com

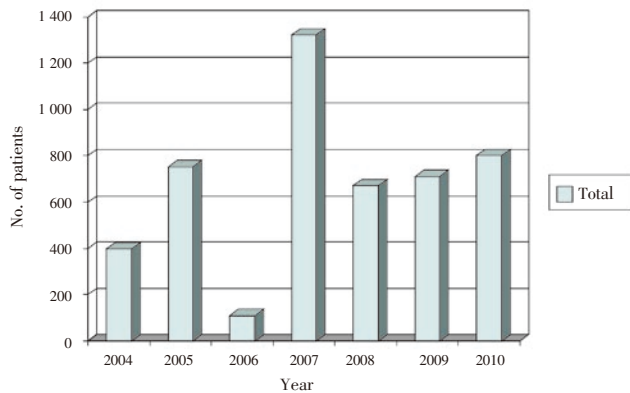


Figure 1. Year wise distribution of CT scan of the brain (2004–2010).

CT scan of the brain of altogether 4 762 patients, *i.e.* 397, 752, 110, 1 322, 671, 710 and 800 in 2004, 2005, 2006, 2007, 2008, 2009 and 2010, respectively was carried out and a year wise representation was shown in Figure 1.

The number of patients varied from 110 (in 2006) to 1322 (in 2007). Out of those 4 762 patients, 1 114 (23.39%) cases were suspected to be suffering from NC having clinical symptoms of epilepsy with convulsions (472), headache (272), right sided weakness (98), loss of consciousness (84), left sided weakness (61), abnormal behavior (48), slurring of speech (34), difficulty in keeping balance of the body (33), dementia (12), constituting 42.36, 24.41, 8.79, 7.58, 4.30, 3.05, 2.96, 1.07 percent of the total suspected cases (1 114), respectively.

Ultimately through imaging techniques, out of a total of 1 114 suspected cases, NC was confirmed in 50 (4.48%) of which 34 (68%) were males. The age of the patients varied from 6 to 59 years. Maximum number of cases was found in age groups

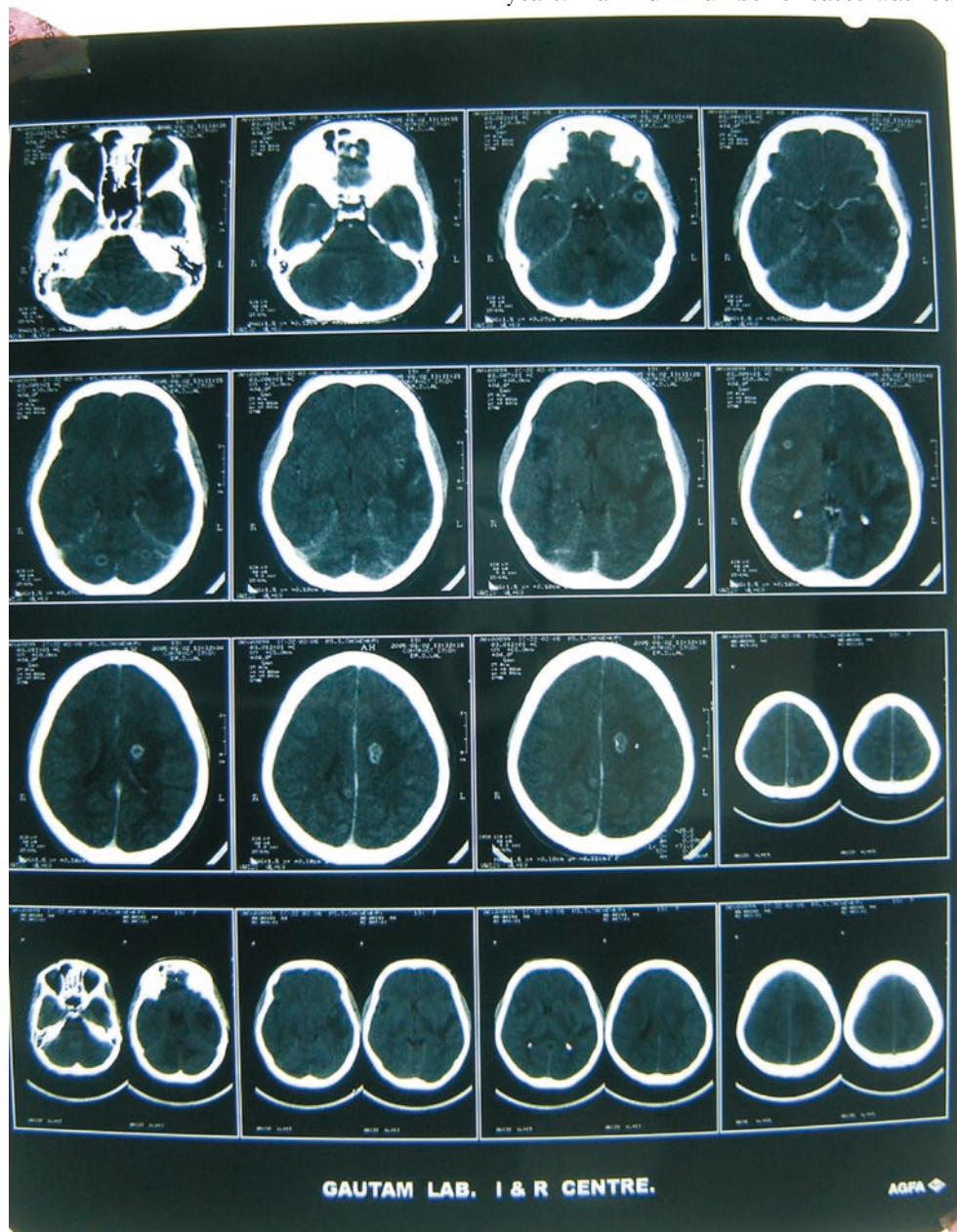


Figure 2. Scattered ring enhancing nodular cystic lesions are seen throughout the brain mainly involving both halves of cerebellum along with bilateral occipital, temporal and parietal cerebral lobes showing adjacent areas of edema—partly obscuring the 4th ventricle, basal subarachnoid cisterns, both sylvian fissures and cortical sulci along with supratentorial ventricles. Septum pellucidum appears mildly shifted towards right side.

between 10 and 39, which was 38 (76%). Out of 50 confirmed cases, 45 (90%) had the clinical symptoms of epilepsy along with convulsion, 2 (4%) had the history of occasional loss of consciousness and 1 (2%) each had history of headache, left sided weakness and difficulty in keeping balance of the body.

Out of 50 cases, 28 (56%) were vegans. In 2004, 2005, 2006, 2007, 2008, 2009 and 2010, the number of NC cases was 9, 23, 2, 8, 4, 3, and 1, respectively with a yearly mean of 7.14.

In our study, four types of lesions were detected[6]. These lesions were calcified lesion (14), small (less than 2 cm) hypodense i.e. vesicular lesion (12), similar hypodense lesion with bright central spot i.e. vesicular lesion with central spot (2) and similar lesion showing ring or disk enhancement (22). We experienced about risk enhancing lesions, which were shown in Figure 2.

Sensitivity and specificity[7,8] of 77 patients having lesions like NC in the brain were determined. Sensitivity indicates how likely patients are to have a positive test if they have the disease whereas specificity defines how likely patients are to have a negative test if they do not have the disease.

Among them, 32 were coded as scan positive for NC where 45 initially doubtful cases were designated as scan negative, of whom in 27, no NC was clinically detected, but in other 18 subjects NC lesions were confirmed (15 cases underwent CT scan for 2nd time and 3 cases performed MRI—known as follow up cases).

Based on the data above we calculated sensitivity and specificity of the CT scan method. Here sensitivity was $32/50=16/25$ or 64% whereas specificity was $27/27=1$ or 100%. So, according to our study model, a CT scan can correctly diagnose 64% of NC cases.

4. Discussion

NC is a global disease[1,2]. Approximately, 50 million persons are infected worldwide and about 50 000 die of NC yearly[9]. Diagnosis of NC in early stage is essentially needed for effective treatment. The role of CT scan of the brain in diagnosing NC cases, where no other laboratory procedures have been performed, is evaluated. Of 1 114 suspected cases, on examining CT scan of the brain, 77 cases have been provisionally diagnosed as NC cases, but on further analysis and MRI studies, 50 patients are confirmed to be suffering from NC. Most important drawback of serological tests is cross reactivity with other helminthic infections[10] and NC is better diagnosed by medical imaging techniques[5]. Out of 77 cases, we have to take help of MRI in 27 to arrive at a logical conclusion (100% specific).

This investigation clearly demonstrates the existence of NC in an area of central Kolkata in all the years of the study period, the number of cases varying from 2 (2006) to 23 in 2005 with a yearly mean of 7.14. This perennial occurrence of NC indicates that this parasitic disease is very much endemic in this area and it is a significant but under-recognized public health problem in Kolkata. Through collection and analysis of such recent data, the area of prevalence of NC may be marked, the intensity of infection may be judged, and the appropriate preventive measures may be advocated.

The specificity and sensitivity of CT scan of the brain in diagnosing NC have been determined which are 64% and 100%, respectively.

NC can occur in any age and any gender may be affected. In our study, the maximum number of patients i.e. 38 (76%) belong to 10 to 39 years of age group showing that infection

is more common in young and in adult age than in any other age groups. Another important feature is worth mentioning. According to our data, 56% of vegans (28) have been infected. A majority of the people in the study area is vegan indicating that most of these NC infections have occurred through contaminated unwashed, uncooked or undercooked vegetables[6], not through infection via faeco-oral route or through eggs of *Taenia solium* that enter the stomach of the infected person possessing the adult worm in the intestine. The government and different health organizations should take responsibilities to educate people in right direction about this disease. Some primary guidelines can be documented to prevent these types of endemic neurological disease. The concept of individual hygienic system despite of any religion or race provision of sanitation and sanitary water supply and most importantly proper way of washing and cooking of vegetables can reduce the risk of attack.

Conflict of interest statement

We declare that we have no conflict of interest.

Acknowledgements

We are thankful to the directors of the Gautam Laboratories—Imaging and Research Center, Mr. Kamal Kumar Mukim, Mr. Dilip Das and Dr. Basab Mandal for giving us the facilities to conduct this study. We also acknowledge the persuasion of Mr. Kallol Sarkar and Mr. Rabindranath Maity of the same organization for their sincere contribution in this study.

References

- [1] Kraft R. Cysticercosis: an emerging parasitic disease. *Am Fam Physician* 2007; **76**(1): 91–96.
- [2] Singhi P. Neurocysticercosis. *Ther Adv Neurol Disord* 2011; **4**(2): 67–81.
- [3] Winkler AS, Willingham AL, Sikasunge CS, Schmutzhard E. Epilepsy and neurocysticercosis in sub-Saharan Africa. *Wien Klin Wochenschr* 2010; **121**(3): 3–12.
- [4] Vassallo M, Allen S. An unusual cause of dementia. *Postgrad Med J* 1995; **71**: 483–484.
- [5] Dias MD, Alves L, Tovar-Moll F, Peralta RHS, Peralta JM, Sohler MP. Persistence of viable cysts in neurocysticercosis: a serial imaging study. *Rev Bras Neurol* 2010; **46**(4): 13–16.
- [6] Cook CG, Zumla AI. *Manson's tropical diseases*. 22nd ed. London: W.B. Saunders; 2009, p. 1572–1573.
- [7] Xu JM, Acosta LP, Hou M, Manalo DL, Jiz M, Jarilla B, et al. Seroprevalance of cysticercosis in children and young adults living in a helminthic endemic community in Leyte, the Philippines. *J Trop Med* 2010; **2010**: 603174. doi:10.1155/2010/603174.
- [8] Handali S, Klarman M, Gaspard AN, Noh J, Lee YM, Rodriguez S, et al. Multiantigen print immunoassay for comparison of diagnostic antigens for *Taenia solium* cysticercosis and taeniasis. *Clin Vaccin Immunol* 2010; **17**(1): 68–72.
- [9] Malla N, Mahajan RC. Cysticercosis and epilepsy: need for better sanitation, personal hygiene and swine husbandry practices. *Everyman's Sci* 2010; **45**: 203–206.
- [10] Pal DK, Carpio A, Sander JWAS. Neurocysticercosis and epilepsy in developing countries. *J Neurol Neurosurg Psychiatry* 2000; **68**: 137–143. doi:10.1136/jnnp.68.2.137.