




Contents lists available at ScienceDirect

Asian Pacific Journal of Tropical Disease

journal homepage: www.elsevier.com/locate/apjtd

Document heading

doi:

© 2013 by the Asian Pacific Journal of Tropical Disease. All rights reserved.

Coinfection of *Plasmodium vivax* and Epstein–Barr virus: case reportFatih Akin^{1*}, Celebi Kocaoglu¹, Ece Selma Solak¹, Halil Ozdemir², Bayram Pektaş³, Sukru Arslan⁴¹Department of Pediatrics, Konya Education and Research Hospital, Konya, Turkey²Department of Pediatric Infectious Diseases, Konya Education and Research Hospital, Konya, Turkey³Department of Parasitology, Konya Education and Research Hospital, Konya, Turkey⁴Department of Pediatric Nephrology, Konya Education and Research Hospital, Konya, Turkey

PEER REVIEW

ABSTRACT

Peer reviewer

Sema Gülnar Sensoy, Professor, Ondokuz Mayıs University Faculty of Medicine, Department of Pediatric Infectious Diseases, 55139, Samsun, Turkey.

Tel: +90 362 3121919

Fax: +90 362 4576041

E-mail: sensoyg@gmail.com

Comments

The case is important, because late diagnosis and treatment of malaria in non-endemic regions can cause severe complications of the disease. (Details on Page 75)

Malaria is an acute and chronic illness characterized by paroxysms of fever, chills, sweats, fatigue, anemia, and splenomegaly. It is still an important health problem in malaria-endemic countries. Children living in malaria-endemic areas have elevated Epstein–Barr Virus (EBV) loads in the circulation and acute malaria infection leads to increased levels of circulating EBV that are cleared after anti-malaria treatment. There are many reports about the association of *Plasmodium falciparum* (*P. falciparum*) malaria and EBV infection. Here we report a case who had coinfection of *Plasmodium vivax* (*P. vivax*) malaria and EBV infection. To the best of our knowledge this is the first case indicating the association of *P. vivax* malaria and EBV infection.

KEYWORDS

Plasmodium vivax, Epstein–Barr virus, Coinfection

1. Introduction

Malaria is an acute and chronic illness characterized by paroxysms of fever, chills, sweats, fatigue, anemia, and splenomegaly. It has played a major role in human history, causing harm to more people than perhaps any other infectious disease. Malaria is of overwhelming importance in the developing world today, with an estimated 300 to 500 million cases and more than 1 million deaths each year. Most malarial deaths occur among infants and young children^[1].

It is known that malaria affects EBV persistence as reflected by an increased viral replication. Children living in malaria-endemic areas have elevated EBV loads in the circulation and acute malaria infection leads to increased levels of circulating EBV that are cleared after anti-malaria treatment^[2].

Here we report a case of *Plasmodium vivax* (*P. vivax*) infection who was followed up with the diagnosis of EBV infection.

2. Case report

A 5-year old Turkish boy from Konya admitted to Konya Education and Research Hospital with a history of fever, chills,

and fatigue for six weeks. Fever was high grade up to 40°C and he had fever spikes every other day. There was no history of any cough, vomiting, abdominal pain, joint pain, diarrhea, urinary complaints or drug intake. He had been in Iran for 1 year and had returned to Turkey 2 months ago. He had been followed up with the diagnosis of EBV infection in another hospital.

On admission to our hospital his temperature was 38.8 °C. He had a heart rate of 118/min, respiratory rate of 24/min and blood pressure of 110/70 mmHg. Liver was palpable subcostally 2–3 cm and spleen was 2 cm palpable below the left costal margin. Laboratory investigations revealed: hemoglobin 10.4 g/dL, white blood cell count 4310/mm³ (neutrophils 36%, lymphocytes 60%, and monocytes 4%) platelet count 152000/mm³, sedimentation rate 65 mm/h, and CRP 15.7 mg/L. Thin smear of peripheral blood showed ameboid trophozoites of *P. vivax* (Figure 1). EBV viral capsid antigen (VCA) IgM, EBV VCA IgG and EBNA IgG was positive and other antibodies against viral pathogens including cytomegalovirus, herpes simplex virus, rubella, toxoplasma, parvovirus B19 and hepatitis A, B, C viruses were negative. Results of the cultures of blood and urine were also negative. Biochemical analysis were within normal levels. Laboratory investigations made at the prior hospital performed

*Corresponding author: Dr. Fatih Akin, Konya Training and Research Hospital, 42040 Meram, Konya, Turkey.
Tel: 0903323236709
Fax: 0903323236723
E-mail: drfatihakin@gmail.com

Article history:

Received 4 Nov 2012

Received in revised form 8 Nov, 2nd revised form 13 Nov, 3rd revised form 17 Nov 2012

Accepted 28 Dec 2012

Available online 28 Feb 2013

20 d ago revealed: hemoglobin 10 g/dL, white blood cell count 5210/mm³, platelet count 128000/mm³, EBV VCA IgM positive and EBV EBNA IgM negative. The diagnosis of EBV infection was made and no medications were given.

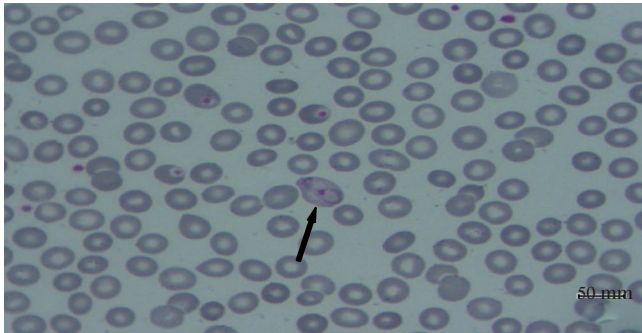


Figure 1. Ameboid trophozoite of *P. vivax* seen on thin smear of peripheral blood.

As we obtained the diagnosis of *P. vivax* malaria he was treated with chloroquine once orally at 10mg/kg first dose, followed by 5 mg/kg in three doses over the next 6, 24 and 48 h and primaquine at 0.6 mg/kg in four divided doses a day for 14 d. He was no longer febrile after 2 d of treatment. *P. vivax* trophozoites were disappeared on peripheral blood smear on the third day of treatment. 1 week after completing the treatment laboratory analysis revealed: hemoglobin 12.8 g/dL, white blood cell count 7780/mm³ and platelet count 164000/mm³.

3. Discussion

P. vivax malaria is an important health problem in malaria-endemic countries. Despite all eradication practices it's still endemic in the South-east Anatolia and Cukurova regions of Turkey. *P. vivax* is the most common cause of malaria agent in Turkey with rare *P. falciparum* and *Plasmodium malariae* cases. Most of these cases in our country has a history of traveling to malaria-endemic countries[3]. Our patient also had a traveling history to Iran for 1 year.

Seroepidemiological studies have shown that about 91% of the adults worldwide have had first time infection by EBV. In developing countries, first-time infection by EBV is more frequent in the first decade of life[4]. Once EBV infection has occurred, it remains for the lifetime of the individual, making EBV one of the most persistent viruses that infect humans[5].

It is known that malaria affects EBV persistence as reflected by an increased viral replication. Children living in malaria-endemic areas have elevated EBV loads in the circulation and acute malaria infection leads to increased levels of circulating EBV that are cleared after anti-malaria treatment[2]. There are many reports about the association of *P. falciparum* malaria and EBV infection. Moormann *et al.* reported that *P. falciparum* malaria induces polyclonal B-cell expansion and lytic EBV reactivation leading to the expansion of latently infected B-cells[6]. Additionally they mentioned that EBV specific T-cell immunity is impaired during *P. falciparum* malaria either as a cause or consequence of enhanced EBV replication leading to loss of viral control[6]. Coinfection of *P. vivax* malaria and EBV infection was present in our patient. He had positive EBV VCA IGM levels that lead to missed diagnosis of malaria for nearly 1 month. To the best of our knowledge this is the first case suggesting the association of *P. vivax* malaria and EBV infection.

Early diagnosis and prompt treatment of malaria is important for prevention of complications such as severe anemia,

seizures, impaired consciousness, respiratory distress, coma, hypoglycemia and circulatory collapse[1]. Treatment of our patient was started before these complications occurred, and he recovered completely.

In conclusion, physicians practicing in nonendemic areas should consider the diagnosis of malaria in any febrile child who has returned from a malaria-endemic area within the previous year. It should not be forgotten that EBV infection may accompany malaria, because malaria affects EBV persistence as reflected by an increased viral replication. Because delay in diagnosis and treatment can result in severe illness or death, earlier diagnosis and prompt treatment of malaria is crucial for prevention of its complications.

Conflict of interest statement

We declare that we have no conflict of interest.

Comments

Background

Epstein-Barr virus establish a life long infection within the human host following primary infection. *P. falciparum* infection can contribute to EBV reactivation in the blood.

Related reports

Other studies in this area reported that Plasmodium falciparum infection caused increased titers of EBV infection.

Peer review

In this case, authors reported a 5-year old Turkish boy, who had lived in Iran for 1 year and returned to Turkey 2 months ago. They diagnosed co-infection of *P. vivax* and EBV in the child for the first time. The case is important, because late diagnosis and treatment of malaria in non-endemic regions can cause severe complications of the disease.

References

- [1] John CC, Krause PJ. Malaria (Plasmodium). In: Kliegman RM, Stanton BF, Behrman RE, St. Geme JW, Schor NF, editors. *Nelson textbook of pediatrics*. 19th ed. Philadelphia: Elsevier Saunders; 2011, p. 1198–1207.
- [2] Chêne A, Nylén S, Donati D, Bejarano MT, Kironde F, Wahlgren M, et al. Effect of acute *Plasmodium falciparum* malaria on reactivation and shedding of the eight human herpes viruses. *PLoS One* 2011; **6**(10): e26266.
- [3] Karahocagil MK, Baran AI, Yaman G, Çiçek M, Bilici A, Binici I, et al. Case report: two *Plasmodium vivax* malaria cases in the Van Province. *Turkiye Parazitoloj Derg* 2009; **33**(2): 172–173.
- [4] Saldaña NG, Colín VAM, Ruiz GP, Olguin HJ. Clinical and Laboratory characteristics of infectious mononucleosis by Epstein-Barr virus in Mexican children. *BMC Res Notes* 2012; **5**: 361.
- [5] Serraino D, Piselli P, Angeletti C, Scuderi M, Ippolito G, Capobianchi MR. Infection with Epstein-Barr virus and cancer: an epidemiological review. *J Biol Regul Homeost Agents* 2005; **19**(1–2): 63–70.
- [6] Moormann AM, Snider CJ, Chelimo K. The company malaria keeps: how co-infection with Epstein-Barr virus leads to endemic Burkitt lymphoma. *Curr Opin Infect Dis* 2011; **24**(5): 435–41.