




Contents lists available at ScienceDirect

## Asian Pacific Journal of Tropical Disease

journal homepage: [www.elsevier.com/locate/apjtd](http://www.elsevier.com/locate/apjtd)

Document heading

doi:

© 2013 by the Asian Pacific Journal of Tropical Disease. All rights reserved.

## Pattern of abnormal ultrasonographic findings in patients with clinical suspicion of chronic liver disease in Sokoto and its environs

Sadisu Mohammrd Ma`aji<sup>1\*</sup>, Abdulmuminu Yakubu<sup>2</sup>, Daniel Dirioha Odunko<sup>3</sup><sup>1</sup>Department of Radiology, Usmanu Danfodiyo University, Teaching Hospital Sokoto, Nigeria<sup>2</sup>Department of Medicine Usmanu Danfodiyo University Teaching Hospital Sokoto, Nigeria<sup>3</sup>Department of Radiology, Federal Medical Centre Birnin Kebbi, Nigeria

## PEER REVIEW

## ABSTRACT

**Peer reviewer**

Dr. Anthony Udo Eka, Medical Imaging Ghana Limited, 17 Ridge Road, Roman Ridge, Accra, Ghana.  
Tel: +233-263182567  
E-mail: drtonyeka@yahoo.com

**Comments**

This is a good article which highlights the role of ultrasonography in the evaluation of patients with chronic liver disease. The multi centre approach to the study is indicative of the possibility of doing more of these types of studies.  
(Details on Page 205)

**Objective:** To analyse the various abnormal transabdominal ultrasound findings in patients with clinical suspicion of chronic liver disease in our environment with a view of comparing our findings with other existing literatures. **Methods:** A total of 61 consecutive patients with clinical signs and symptoms of chronic liver disease attending medical outpatient clinic at the Department of Medicine, Usmanu Danfodiyo University, Teaching Hospital Sokoto and Federal Medical Centre Birnin Kebbi were scanned at Radiology Departments for any abnormal intra-abdominal findings from May 2011 to April 2012. All the patients were scanned with Apogee 800 plus (Japan 2002) and Concept D (Dynamic Imaging Scotland) Ultrasound scanners with a variable frequency probes at 5–12 MHz. **Results:** A total of 61 abdominal ultrasounds were performed during this study period. All the cases met the inclusion criteria. The mean age was (46.0±12.6) years (ranged 50 years). The mean liver size was (13.25±1.48) cm (ranged 11 cm) and (14.00±0.77) cm (ranged 0.77 cm) for right and left lobe respectively. The mean spleen size was (15.90±1.22) cm (ranged 6 cm). The sex distribution was males 43 (70.49%) and females 18 (29.5%). Of the 61 cases included, the indication for the abdominal ultrasonography were hepatitis 1 (1.6%), liver cirrhosis 20 (50.82%), obstructive jaundice 2 (3.28%), chronic liver disease 25 (40.98%) and chronic abdominal swelling 2 (3.2%). **Conclusions:** In conclusion, our study has demonstrated various abnormal transabdominal ultrasound findings in patients suspected with chronic liver disease in our locality. Ultrasound is useful in the diagnosis of chronic liver disease in daily clinical practice. However, the sensitivity can be improved if a high frequency probe is used and done by experienced and dedicated operators. Liver biopsy remains the gold standard especially when patients are clinically asymptomatic.

## KEYWORDS

Ultrasound, Patterns, Abnormal findings, Liver disease, Ultrasonography, Chronic liver disease

### 1. Introduction

Chronic liver disease (CLD) is a disease of the liver resulting from an inflammatory, infiltrative, immunologic, mechanical or metabolic injury to the liver, which has persisted for six or more months without complete resolution<sup>[1]</sup>. The leading causes, worldwide of chronic liver

disease are hepatitis B virus (with or without hepatitis D virus), hepatitis C virus (HCV) and alcohol. An estimated 600 000 persons die each year due to acute and chronic consequences/sequel of Hepatitis B virus<sup>[2]</sup>. Approximately 3% of the world population, 170 million people, are chronically infected by HCV. Other causes of CLD are viral hepatitis (hepatitis B and D, cytomegalovirus, Epstein

\*Corresponding author: Dr. Sadisu Mohammrd Ma`aji, Department of Radiology, Usmanu Danfodiyo University, Teaching Hospital, Sokoto, Nigeria.  
Tel: +2348037019142  
Fax: 060230334  
E-mail: drsadisu@yahoo.com

## Article history:

Received 20 Feb 2013

Received in revised form 24 Feb, 2nd revised form 28 Feb, 3rd revised 5 Mar 2013

Accepted 15 Apr 2013

Available online 28 Jun 2013

Barr virus), toxoplasmosis, schistosomiasis, inherited and metabolic disorders, drugs and toxins *etc*[3].

Cirrhosis and chronic liver failure together were the 12th most common cause of death in the United States in 2002, accounting for 27257 deaths (9.5 per 100000 persons), with a slight male predominance[4]. Approximately 40 percent of patients with cirrhosis are asymptomatic, and the condition often is discovered during a routine examination with laboratory or radiographic studies, or at autopsy. Liver biopsy is the gold standard for diagnosing this condition.

Ultrasound imaging is a popular and non-invasive tool frequently used in the diagnoses of liver diseases. The analysis of ultrasound images can be viewed as the problem of texture classification, because liver's ultrasound images have various granular structures described by texture[5]. Ultrasound is the initial examination performed in most patients with suspected hepatic or spleen abnormality. Interrogation with ultrasound is the best performed using a 5 MHz curvilinear probe, but in large patients, a low frequency probe may be necessary. The liver is divided into right and left lobes by the middle hepatic vein.

An ultrasound evaluation of the liver fibrosis stage of chronic liver disease has been performed by assessing various ultrasound factors such as the liver size, the bluntness of the liver edge, the coarseness of the liver parenchyma, nodularity of the liver surface, the size of the lymph nodes around the hepatic artery, the irregularity and narrowness of the inferior vena cava, portal vein velocity or spleen size[6,7–11]. Some of the parameters were used to carry out this study. Information on the pattern of abnormal ultrasonographic findings in patients with clinical suspicion of chronic liver disease is scanty in Nigeria ,especially from the north–western region. Our aim is to document those abnormalities in our environment.

## 2. Materials and methods

After obtaining ethical clearance from the ethical committee of the hospital and informed consent was obtained from the patients, a total of 61 consecutive patients with clinical signs and symptoms of chronic liver disease attending medical outpatient clinic at the Department of Medicine, Usmanu Danfodiyo University, Teaching Hospital Sokoto and Federal Medical Centre Birnin Kebbi were prospectively scanned at Radiology Departments for any abnormal intra–abdominal findings from May 2011 to April 2012. The exclusion criteria were patients with confirmed liver biopsy or diagnosis of chronic liver disease. Patients with cardiac cirrhosis and tropical splenomegaly syndrome were also excluded in this study.

All the patients were scanned with Apogee 800 plus (Japan 2002) and Concept D (Dynamic Imaging Scotland) Ultrasound scanners with a variable frequency probes at 5–12 MHz. After the patient fasted overnight, the examination was

performed with the patient in the supine, right or left side position to obtain an optimal view of the abdominal viscera. Measurement of the liver and spleen was performed; the size of the liver was measured in the right MCL (with measurement from the hepatic dome to the inferior hepatic tip) according to the method described by Börner *et al* [12]. In addition, liver parenchymal changes outline and nodularity of liver surface and any other abnormal abdominal findings were documented.

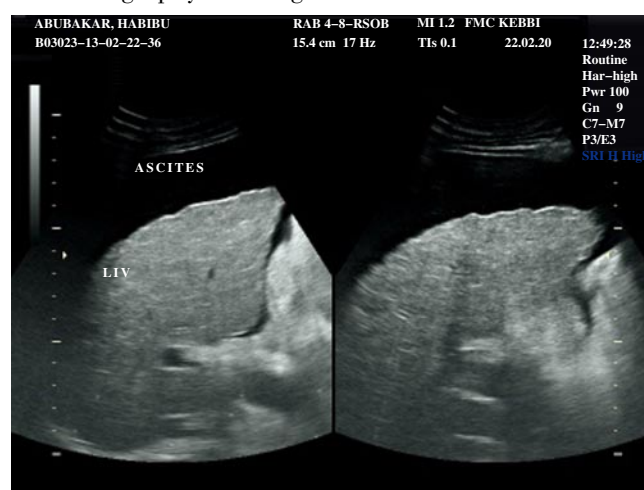
The collected data were analysed using the statistical Package for scientific Solusions (SPSS) version 17. Mean, standard deviation and ranges were used as appropriate to describe continuous variables. Significance was presumed for  $P < 0.001$ .

## 3. Results

A total of 61 abdominal ultrasounds were performed during this study period. All the cases met the inclusion criteria. The mean age was  $(46.0 \pm 12.6)$  years (ranged 50 years). The mean liver size was  $(13.25 \pm 1.48)$  cm (ranged 11 cm) and  $(14.00 \pm 0.77)$  cm (ranged 0.77 cm) for right and left lobe respectively. The mean spleen size was  $(15.9 \pm 1.22)$  cm (ranged 6 cm).

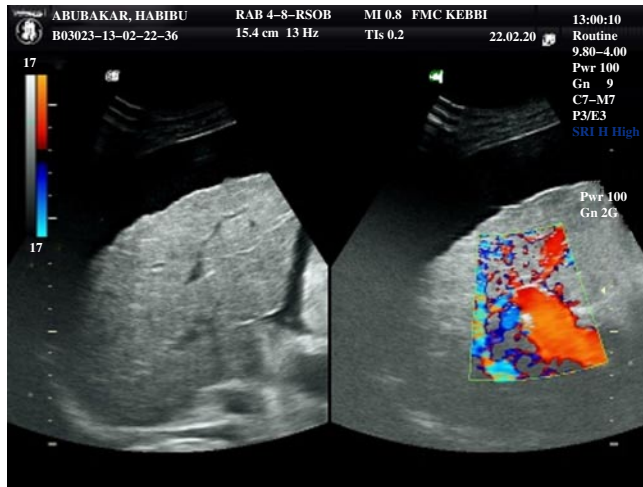
The sex distribution was males 43 (70.49%) and females 18 (29.5%). Of the 61 cases included, the indication for the abdominal ultrasonography were hepatitis 1 (1.6%), liver cirrhosis 20 (50.82%), obstructive jaundice 2 (3.28%), chronic liver disease 25 (40.98%) and chronic abdominal swelling 2 (3.2%).

Gallbladder wall thickening was demonstrated in 49 (80.33%) of the patients while 12 (19.67%) showed normal gallbladder wall. Ascites was demonstrated in 45 (73.77%) of the patients, and the remaining 16 (26.23%) of the patients had no ascites. Destroyed intrahepatic vascular architecture was demonstrated in 58 (95%) while 3 (4.9%) showed normal vascular architecture. Figure 1 is a longitudinal Ultrasonography showing a shrunken liver and ascites.



**Figure 1.** A longitudinal gray scale ultrasound image of the abdomen showing shrunken and irregular liver edge with ascites.

Figure 2 is a Longitudinal Ultrasonography showing a nodular and shrunken liver with gross gallbladder wall thickening.



**Figure 2.** A Gray scale and Doppler ultrasound images of the liver showing hemodynamic alteration of intrahepatic vasculature.

#### 4. Discussion

In clinical practice, ultrasound is currently used to predict the presence of chronic liver disease in two ways. The first finding is to examine portal hypertension, and the other by examining the size, lobar ratio, echogenicity and echo texture of the liver. Some of these parameters were used to carry out this study.

The diagnosis of liver cirrhosis is important in the further management and monitoring of patients. Even though liver biopsy is considered the gold standard, it carries a false negative rate of 10% to 20%[13,14].

Typically, CLD is established with the presence of hepatitis which can evolve to the end-stage of CLD-cirrhosis. In the cirrhosis stage, there are two phases – asymptomatic and symptomatic stage. Liver biopsy has an important role in the evaluation and staging of CLD. Nevertheless, due to its invasive nature and the improved accuracy of noninvasive tests, its importance has been diminished. In particular, ultrasound as proven to be a useful diagnostic procedure for CLD.

This study shows that CLD is common in both sexes with slight male predominance (43%) similar to that reported internationally[15-17]. Irregularities of liver edge were seen in 93% cases and only 6.6% showed normal liver edge. However a study done by Mahjabeen *et al.* showed 32% of and 68% of cases for irregular and normal liver edge respectively[18]. Although, coarsening of hepatic parenchymal echo texture and irregular outlines were subjective signs, 95% and 4.9% of cases showed heterogeneous and homogenous echo texture respectively in our study. Weickert *et al.* conducted a prospective study on 100 patients by doing their ultrasound

prior to biopsy also following the similar parameters laid down in our study. Results showed ultrasound examination was sensitivity of 55% and specificity of 86 % [19].

The normal span of the adult liver is 15 to 17 cm. The most reliable measurement is probably the sagittal dimension from the dome to the tip of the right lobe, measured at the midclavicular line.

If this exceeds 15.5 cm, the liver is probably enlarged. Hepatomegaly can be confidently diagnosed when the liver extends caudal to the right kidney and the left lobe is subjectively of normal size or larger. The use of this approach may be inaccurate in the occasional patient with a Riedel lobe.

Three-dimensional techniques in CT, magnetic resonance imaging, and sonography ultimately promises to make accurate volumetric measurements feasible.

Ultrasound is a useful imaging technique, which can provide essential information in all forms of chronic liver disease. In our study, ultrasonographic hepatomegaly was seen in 31% cases and it was shrunken in 25%, signifying that in CLD, one may have an enlarged to a fibrosed liver depending upon severity and chronicity of underlying disorder. These findings are similar to the work of Hanif *et al.*[20]. Hepatomegaly is difficult to diagnose objectively with sonography.

Ultrasonographic splenomegaly was seen in 97% cases with disruptions or destroyed vascular architecture seen in 95% as a sign of portal hypertension.

Ascites was the major presenting symptoms in the present study, being at 74% which was similar to the work of Hanif *et al.* that got 80% as oppose to 30% reported by Malik *et al.* and 50% reported in another study by Mehnaz *et al.*[20-22]. This high incidence of ascites in our study indicates fairly advanced disease with decomposition. In our study, portal vein was dilated in 41% cases. The multidimensional value of ultrasound was quite obvious. It has been extensively studied in the last two decades, but the result has been variable. Neshiura *et al.* did ultrasound evaluation of liver fibrosis stage by the simultaneous use of low and high frequency probes. They followed the same course in their study like us by establishing the ultrasound parameters, such as liver edge, margins and parenchyma echo texture. They found out that liver edge was not as specific for evaluation of liver fibrosis as margins and echo texture[23]. However, Choong *et al.* reported that routine clinical ultrasound was not a sensitive predictor of early fibrosis in chronic viral hepatitis. Their findings suggested nodularity to be the most sensitive sonographic feature for the detection of significant fibrosis[24]. Ultrasound of the liver surface is a useful diagnostic tool in patients at risk of CLD when assessing whether they should undergo a liver biopsy[25]. In contrast, Lee *et al.* suggested that four variables (platelet count <100 000 / $\mu$ L, albumin level <3.5 g/dL, INR >1.3, and

surface nodularity) can be used for identification of liver cirrhosis in patients with chronic viral hepatitis with high specificity<sup>[26]</sup>. Martinez *et al.* advocated the need to stage liver fibrosis using liver biopsy, however, should decrease as treatment options become more successful (as has occurred with viral hepatitis) and suggested the use of noninvasive tests that have demonstrated a reasonable ability to identify significant fibrosis, cirrhosis in particular. However, only those tests with the highest diagnostic accuracy, cost-effectiveness, and availability should be implemented<sup>[27]</sup>.

The limitation of our study was the relative small number of patients. Nevertheless, we felt that a retrospective review will give us an insight into the usefulness of ultrasonography in the diagnosis of chronic liver in our daily clinical practice outside the context of a clinical trial.

In conclusion, our study has demonstrated various abnormal transabdominal ultrasound findings in patients suspected with chronic liver disease in our locality. The most common abnormalities we found are destroyed intrahepatic vascular architecture, gallbladder wall thickening and ascites in that order. Ultrasound is useful in the diagnosis of chronic liver disease in daily clinical practice. However, the sensitivity can be improved if a high frequency probe is used and done by experienced and dedicated operators. Liver biopsy remains the gold standard especially when patients are clinically asymptomatic. Future research correlating the abnormal findings with liver biopsy as well as clinical and laboratory parameters will help in definitive diagnosis.

### Conflict of interest statement

We declare that we have no conflict of interest.

### Acknowledgements

We thank all that help us to carry out this work.

### Comments

#### Background

Chronic liver disease is increasingly becoming a disease of pandemic proportions. It becomes imperative for the radiological findings of the disease to be properly documented by radiologists who come in contact with patients who present with the disease. This study has brought to the fore the usefulness of ultrasound as a diagnostic tool in the management of chronic liver disease.

#### Research frontiers

This study was carried out in two different centres in North

Western Nigeria. The size of the liver was obtained in the mid-clavicular line with measurements from the hepatic dome to the inferior hepatic tip according to the method described by Borner *et al.* In addition, changes in the liver outline, parenchymal distortions and nodularity of the surface of the liver were also documented.

#### Related reports

This study is at variance with the study done by Mahjabeen *et al.* with respect to the findings of liver edge irregularities and normal liver edge. This study reports a finding of 93% and 6.6% respectively, while that of Mahjabeen *et al.* reported a finding of 32% and 68% respectively. The finding of hepatomegaly and shrunken liver (31% and 25% respectively) was similar to that of Hanif *et al.* In this study, ascites was found in 74% of cases and this agrees with the study done by Hanif *et al.* who reported a prevalence of 80%. However, Malik *et al.* reported a finding of 30% and Mehnaz *et al.* reported a finding of 50%.

#### Innovations & breakthroughs

Documentation of findings of liver edge, margins and parenchymal abnormalities, as well as portal vein diameter in the evaluation of liver fibrosis.

#### Applications

The findings in this study can be applied to everyday practice by radiologists in the evaluation of patients with chronic liver disease.

#### Peer review

This is a good article which highlights the role of ultrasonography in the evaluation of patients with chronic liver disease. The multi centre approach to the study is indicative of the possibility of doing more of these types of studies. The sample size was small. A further study with a larger sample size is suggested.

### References

- [1] Edemariam T. The liver. In: Parry E, Geoffrey R, Mabey D, Gill G, editors. *Principles of medicine in Africa*. 3rd ed. Cambridge: Cambridge University Press; 2004, p. 991–1007.
- [2] Nathan F, Catherine K, Kasha S, Edward JM, Graham C, Adeeba K. Chronic hepatitis C treatment outcomes in low- and middle-income countries: a systematic review and meta-analysis. *Bull World Health Organ* 2012; **90**: 540–550.
- [3] Ghany M, Hoofnagle JH. Liver and biliary tract disease. In: Braunwald E, Fauci AS, Kasper DL, editors. *Principles of internal medicine*. 15th ed. New York: Mc Graw Hill; 2001, p. 1707–1711.
- [4] National Center for Health Statistics. National Vital Statistics Report. Chronic liver disease/cirrhosis. Hyattsville: National

- Center for Health Statistics; 2006. [Online] Available from: <http://www.cdc.gov/nchs/fastats/liverdis.htm>. [Accessed on 2nd May, 2006].
- [5] Thijssen JM. Ultrasonic speckle formation, analysis and processing applied to tissue characterization. *Pattern Recogn Lett* 2003; **24**(4-5): 659-675.
- [6] Fontana RJ, Lok ASF. Noninvasive monitoring of patients with chronic hepatitis C. *Hepatology* 2002; **36**: S57-S64.
- [7] Celle G, Savarino V, Picciotto A, Magnolia MR, Scalabrini P, Doderio M. Is hepatic ultrasonography a valid alternative tool to liver biopsy? Report on 507 cases studied with both techniques. *Dig Dis Sci* 1988; **33**: 467-471.
- [8] Gaiani S, Gramantieri L, Venturoli N, Piscaglia F, Siringo S, D'Errico A, et al. What is the criterion for differentiating chronic hepatitis from compensated cirrhosis? A prospective study comparing ultrasonography and percutaneous liver biopsy. *J Hepatol* 1997; **27**: 979-985.
- [9] Tüney D, Aribal ME, Ertem D, Kotiloğlu E, Pehlivanoglu E. Diagnosis of liver cirrhosis in children based on colour Doppler ultrasonography with histopathological correlation. *Pediatr Radiol* 1998; **28**: 859-864.
- [10] Khan KN, Yamasaki M, Yamasaki K, Inoue O, Yatsuhashi H, Koga M, et al. Proposed abdominal sonographic staging to predict severity of liver diseases: analysis with peritoneoscopy and histology. *Dig Dis Sci* 2000; **45**: 554-564.
- [11] Nicolau C, Bianchi L, Vilana R. Gray-scale ultrasound in hepatic cirrhosis and chronic hepatitis: diagnosis, screening, and intervention. *Semin Ultrasound CT MR* 2002; **23**: 3-18.
- [12] Börner N, Schwerk WB, Braun B. Leber. In: Braun B, Günther R, Schwerk WB, editors. *Ultraschalldiagnostik*. Landsberg: Ecomed; 1987, p. 1-18.
- [13] Colombo M, Del Nino E, de Franchis R, De Fazio C, Festorazzi S, Ronchi G, et al. Ultrasound-assisted percutaneous liver biopsy: superiority of the Tru-Cut over the Menghini needle for diagnosis of cirrhosis. *Gastroenterology* 1988; **95**: 487-489.
- [14] Pagliaro L, Rinaldi F, Craxi A, Di Piazza S, Filippazzo G, Gatto G, et al. Percutaneous blind biopsy versus laparoscopy with guided biopsy in diagnosis of cirrhosis. A prospective, randomised trial. *Dig Dis Sci* 1983; **28**: 39-43.
- [15] Bortolotti F, Calzia R, Vagnente A, Cadrobbi P, Rugge M, Armigliato M, et al. Chronic hepatitis in childhood: the spectrum of disease. *Gut* 1988; **29**: 559-564.
- [16] Mehnaz A. Chronic liver disease in children. An overview. *Med Spect* 1999; **20**: 7-11.
- [17] Danowal TR, Agarwal V, Malhotra V, Baveja U, Mittal SK. Clinical spectrum of chronic liver disease in north Indian children. *Trop Gastroenterol* 1997; **18**: 174-176.
- [18] Mahjabeen M, Kamal MN, Muhammad U. Sensitivity and specificity of ultrasonography in the early diagnosis of liver fibrosis stage in patients with chronic liver disease. *Ann Pak Inst Med Sci* 2009; **5**(4): 237-241.
- [19] Uwe W, Andrea B, Jakob R, Schilling D, Axel E, Jurgen R. Diagnosis of liver cirrhosis: A comparison of modified ultrasound and laparoscopy in 100 consecutive cases. *J Clin Gastroenterol* 2005; **39**: 529-532.
- [20] Hanif M, Raza J, Qureshi H, Issani Z. Etiology of chronic liver disease in children. *J Pak Med Assoc* 2004; **54**(3): 119-122.
- [21] Malik MA, Hussain W, Aslam M, Maqbool S. Clinical spectrum of chronic liver disease in Pakistani hospitalized children. *Pak Pediatr J* 2000; **24**: 9-12.
- [22] Mehnaz A. Chronic liver disease in children. An overview. *Med Spect* 1999; **20**: 7-11.
- [23] Nishiura T, Watanabe H, Ito M, Matsuoka Y, Yano K, Daikoku M. Ultrasound evaluation of fibrosis stage in chronic liver disease by simultaneous use of high and low frequency probes. *Br J Radiol* 2005; **78**: 189-197.
- [24] Choong C, Venkatesh SK, Siew EP. Accuracy of routine clinical ultrasound for staging of liver fibrosis. *J Clin Imaging Sci* 2012; **2**: 58.
- [25] Richard A, Kerry T, Phillips M. Accuracy of ultrasound to identify chronic liver disease. *World J Gastroenterol* 2010; **16**(28): 3510-3520.
- [26] Lee HS, Kim JK, Cheong JY, Han EJ, An SY, Song JH, et al. Prediction of compensated liver cirrhosis by ultrasonography and routine blood tests in patients with chronic viral hepatitis. *Korean J Hepatol* 2010; **16**: 369-375.
- [27] Martinez SM, Crespo G, Navasa M, Forn X. Noninvasive assessment of liver fibrosis. *Hepatology* 2011; **53**: 325-335.

---

## Welcome submissions

Asian Pacific Journal of Tropical Disease (*APJTD*) aims to establish and provide an international academic communicating platform for physicians, medical scientists, allied health scientists and public health workers, especially those of the Asian Pacific region and worldwide on tropical disease. *APJTD* expects to publish more excellent papers on tropical disease.

Methods of submission: mail the manuscript to the E-mail address [apjtdd@gmail.com](mailto:apjtdd@gmail.com)

Welcome to submit your great articles to *APJTD*!