



Contents lists available at ScienceDirect

Asian Pacific Journal of Tropical Disease

journal homepage: www.elsevier.com/locate/apjtd

Document heading

doi: 10.1016/S2222-1808(14)60463-1

© 2014 by the Asian Pacific Journal of Tropical Disease. All rights reserved.

Histopathology of mammary gland in *Staphylococcus aureus* induced mastitis in mice

Jayaraj Fakkirappa Chinchali, Basappa Baswanneppa Kaliwal*

Department of Studies and Research in Biotechnology and Microbiology, Karnatak University, Dharwad, India.

PEER REVIEW

Peer reviewer

Dr. Chandrashekhar Unakal, Associate Professor, Department of Medical Microbiology, School of Biomedical and Laboratory Studies, University of Gondar, Ethiopia, Post Box No. 196.
Tel: +251918153665
E-mail: cg.unakal@gmail.com

Comments

The results are interesting and suggested that increased dose and duration of *S. aureus* inoculum has substantiated effect on mammary tissues of mouse. This is a good study in which the authors evaluated the histopathological changes of mammary gland induced by *S. aureus* in mice. Details on Page S324

ABSTRACT

Objective: To investigate the histopathological changes of mouse mammary tissue damage in dose and durational pathogenicity of *Staphylococcus aureus* (*S. aureus*) inoculums.

Methods: The minimal tissue inflammation dose of *S. aureus* inoculum was determined by inoculating the lactating mice mammary gland to observe the mortality rate at 24, 48, 72 and 96 h of infection for each inoculum dilutions. To study dose pathogenicity, lactating mice were divided into one control and four induced groups of 5 mice each. *S. aureus* inoculums doses of 0.8×10^4 , 1.4×10^5 , 2×10^6 and 2.8×10^7 colony forming unit were inoculated to the induced groups II, III, IV and V respectively. Mice were sacrificed and mammary gland tissues were harvested after 48 h of infection. Similarly to study of durational pathogenicity, a dose of 2×10^7 colony forming unit of *S. aureus* inoculums was inoculated to the induced groups II, III, IV and V respectively. Mice were sacrificed and mammary gland tissues were harvested after 24, 48, 72 and 96 h of infection. Body and mammary gland were weighed and histopathological responses of the tissue damage were observed for both dose and durational pathogenicity's of *S. aureus* inoculums.

Results: The observations indicated mastitis symptoms, decrease in body and mammary gland weights. Histopathological evidences revealed massive infiltration of polymorphonuclear neutrophil leukocytes, damage of alveoli and secretory products as the doses and durations of *S. aureus* inoculum increased compared to the control.

Conclusions: The present study revealed that damage in mammary gland tissue of mice increased as the dose and duration of *S. aureus* inoculums increased.

KEYWORDS

Staphylococcus aureus, Mastitis, Polymorphonuclear neutrophil leukocytes, Mammary gland

1. Introduction

Bovine mastitis is an inflammation of the mammary gland, typically caused by microbial intramammary infection. *Staphylococcus aureus* (*S. aureus*) is the most prevalent infectious bacteria that affect the bovine udder and can provoke clinical mastitis but more frequently

causes subclinical infections that tend to become chronic and difficult to eradicate by conventional antimicrobial therapies[1]. *S. aureus* is historically one of the most important causes of subclinical mastitis and clinical mastitis that becomes chronic[2]. *S. aureus* is an opportunistic bacterial pathogen that can infect, replicate and persist in diverse hosts, including humans and

*Corresponding author: Prof. B. B. Kaliwal, Chairman, P. G. Department of Studies and Research in Biotechnology and Microbiology, Karnatak University, Dharwad-580003, India.

Tel: 91-0836-2779533

Fax: 91-0836-2747884

E-mail: h_kaliwal@yahoo.com; jayaraj_bt2000@yahoo.com

Foundation Project: Supported by the Department of Biotechnology (DBT), Ministry of Science and Technology, Government of India, New Delhi (Grant No. BT/BI/25/001/2006 VOL II dt 05-03-2012)

Article history:

Received 16 Nov 2013

Received in revised form 20 Nov, 2nd revised form 25 Nov, 3rd revised form 29 Nov 2013

Accepted 18 Dec 2013

Available online 28 Jan 2014

domestic animals of economic importance^[3]. After entering the mammary gland through the teat canal and adapting to the udder environment, the bacterial load replicates rapidly, eliciting an inflammatory reaction, infiltration of polymorphonuclear neutrophils (PMN's) into the alveolar space and leading to tissue damage.

The glitches of husbandry, management and cost associated with experimental intramammary infection in the cow, has led to the study of mouse as a model for mastitis. A mouse model of *S. aureus* mastitis was first described by Chandler in 1970^[4]. Since 2000, *S. aureus* has been used to induce mastitis in mice and treat the disease by antimicrobial agents^[5–7]. Many anti-inflammatory and antimicrobial agents are reported and in progress for the treatment of mastitis^[8,9].

Mastitis in dairy animals occurs when the udder becomes inflamed and bacteria invade the teat canal and mammary glands. These bacteria multiply and produce toxins that cause injury to the milk secreting tissue, besides, physical trauma and chemical irritants^[10]. Bacteria may escape from the natural defense mechanisms by multiplication along the streak canal or propulsion into the teat cistern by vacuum fluctuations at the teat end^[11]. The infection occurs after bacteria gain entrance to the mammary gland via the teat canal and evade the cellular and humoral defense mechanisms of the mammary gland to establish disease^[12]. If the infection is not eliminated, bacterial levels in the mammary gland eventually rise to a level at which they begin to damage the mammary epithelium and alveoli in the gland, making them start to lose structural integrity and the blood–milk barrier is breached, leading to visible changes include external swelling of teat, reddening of the gland, and clotting^[11]. Hence, the present study was undertaken to understand the histopathological changes of mouse mammary gland tissue damage, when induced by increasing order of graded doses of *S. aureus* inoculum for a constant time of infection and in another experiment with a constant dose of *S. aureus* inoculum at increasing order of durations of infection.

2. Materials and methods

2.1. Inoculum preparation

The intramammary inocula preparation was based on the method described by Brouillette *et al.* with minor modifications^[13]. *S. aureus* was isolated from a clinical case of bovine mastitis and grown overnight at 37 °C in the tryptic soy broth medium to reach mid–exponential growth. The actual number of colony forming unit (CFU) injected was confirmed by spreading the inoculum onto an agar

plate and counting the colonies after overnight incubation. Bacterial concentration of the culture was determined using a standard curve plotting CFU as a function of the absorbance at 600 nm, the cultures were further serially diluted and suspended in phosphate buffer saline (PBS) to the desired number of CFU/mL.

2.2. Animals

Laboratory bred adult female Swiss albino mice were used in the experiments. Mice aged 90 d old weighing between 25–30 g was used. They were housed in separate polypropylene cages containing sterile paddy husk as bedding material. The mice were provided with standard mice pellet diet Gold Mohar (Krish Scientist's Shoppee, Bangalore) and water *ad libitum*. The mice were maintained under normal day/night schedule (12 : 12) at room temperature (25±2) °C.

2.3. Mouse mastitis model of infection

The intramammary inoculation technique was based on the method described by Brouillette and Malouin^[14]. The lactating mice used for inducing intramammary infection were of 12–14th day of the parturition weighing 35–38 g. The pups were removed 1–2 h before bacterial inoculation of mammary glands and a mixture of ketamine/xylazine at 87 and 13mg/kg of weight, respectively, was used for anesthesia of the lactating mice. A 1 mL syringe with 28 gauge blunt needle was used to inoculate both L₄ (on the left) and R₄ (on the right) abdominal mammary glands. The study was approved by the Institutional Animal Ethical Committee, Department of Biotechnology and Microbiology, Karnatak University, Dharwad, India. Committee for the Purpose of Control and Supervision on Experiments on Animals (Animal House Registration No. 639/02/a/ CPCSEA) guidelines were followed for maintenance and use of the experimental animals.

2.4. *S. aureus* infection profile

To determine the minimal tissue inflammation dose of *S. aureus* inoculum, six groups of six lactating mice each in a group were used. An inoculum of 5×10⁴ CFU of *S. aureus* and its five dilutions of inoculum ranging from 10⁻¹ to 10⁻⁵ was inoculated by intramammary infection through R₄ and L₄ teat canals of the lactating mice mammary gland to observe the mortality rate at 24, 48, 72 and 96 h of infection for each group.

To study dose pathogenicity, lactating mice were divided into one control (group I) and four induced groups (PBS vehicle serves as control) of 5 mice each. *S. aureus*

inoculum (100 µL/gland) doses of 0.8×10^1 , 1.4×10^2 , 2×10^2 and 2.8×10^3 CFU suspended in PBS were inoculated through R₄ and L₄ teat canals of mice for the induced groups II, III, IV and V respectively. Mice were euthanized and mammary gland tissues were harvested after 48 h of intramammary infection. Body and mammary gland were weighed and histopathological responses of the tissue damage were observed.

Similarly, to study durational pathogenicity, lactating mice were divided into one control (group I) and four induced groups (PBS vehicle serves as control) of 5 mice each. A single dose (100 µL/gland) of 2×10^2 CFU of *S. aureus* inoculum suspended in PBS was inoculated through R₄ and L₄ teat canals of the lactating mice for the induced groups II, III, IV and V respectively. Mice were sacrificed and mammary gland tissues were harvested after 24, 48, 72 and 96 h of intramammary infection. Body and mammary gland were weighed and histopathological responses of the tissue damage were observed.

2.5. Histological procedure

For histopathological examination the mammary gland tissues were fixed in aqueous Bouin's fluid for 24 h and dehydrated in graded series of alcohol, cleared in benzene and embedded in paraffin wax. The paraffin blocks were sectioned at 5 µm thicknesses by LEICA RM2255 microtome and the tissue sections were subjected to rehydration by exposing them to decreasing concentrations of alcohol, 100%–10% and then stained with haematoxylin. The sections were dehydrated by using increasing concentrations of alcohol 10%–100% and then stained with eosin. The stained slides were photographed under Axio Imager M2 for histological studies.

2.6. Statistical analysis

Statistical significance between the control and experimental data were subjected to One-way analysis of variance (ANOVA) together with post-hoc Dunnett's test ($P < 0.05$).

3. Results

3.1. Clinical symptoms, body and mammary gland weight

In the present study the inoculated mice were examined daily for local and generalized reactions. Local reactions ranged from darkening of the skin at the base of the teat to obvious swelling of the infected mammary gland. Generalized reactions, when they occurred, included ruffled coat, hunched appearance, weakness and in some cases death. The results revealed that there was 50% mortality in *S. aureus* inoculum 5×10^4 CFU and 40% in the first dilution

at 24 h and consecutive mortality was observed after 48, 72, 96 h of infection and surviving mice were killed at 96 h. The mortality rate observed became the basis to choose the minimal tissue inflammation dose of *S. aureus* inoculum strain to induce the intramammary infection for further studies (Table 1).

Table 1

Clinical observations of mice mastitis induced by *S. aureus*.

Groups	Inoculum (CFU)	Clinical observations at			
		24 h	48 h	72 h	96 h
I	5×10^4	3 D ^a , 3 M	1 D, 2 M	2 D	-
II	10^{-1}	2 D ^b , 4 M	1 D, 3 M	2 D, 1 M	1K
III	10^{-2}	6 M	1 D, 5 M	1 D, 4 M	3D, 1K
IV	10^{-3}	6 M	6 M	1 D, 5 M	2D, 3K
V	10^{-4}	6 M	1 D, 5 M	1 D, 4 M	1D, 3K
VI	10^{-5}	6 M	6 M	1 D, 5 M	1D, 4K

Number of mice in each group is 6 and 2 teats (R₄ and L₄) inoculated, ^a50% mortality, ^b40% mortality. M=symptoms of mastitis, D=dead, K=killed.

There was a significant decrease in body and mammary gland weight at doses 2×10^2 and 2.8×10^3 CFU for 48 h and at durations of 48, 72 and 96 h for 2×10^2 CFU of *S. aureus* inoculum. The body and mammary gland weights of mice were decreased as the doses and durations of the *S. aureus* inoculum increased in the induced groups, respectively, compared to that of control (Table 2 and 3).

Table 2

Effect of graded doses of *S. aureus* inoculum induced mastitis on body and mammary gland weights in mice.

Groups	Inoculum (CFU)	Body weight (g)	Mammary gland weight (g)
I	Control	35.50±1.56	0.286±0.380
II	0.8×10^1	35.30±2.34	0.227±0.420
III	1.4×10^2	35.90±0.98	0.243±0.640
IV	2×10^2	33.70±1.48 ^a	0.178±0.560 ^a
V	2.8×10^3	31.80±1.86 ^a	0.143±0.720 ^a

Values are mean±SEM of 5 animals. ^aSignificant $P \leq 0.05$ v.s. control.

Table 3

Temporal effect of *S. aureus* inoculum induced mastitis on body and mammary gland weights in mice.

Groups	Time of infection (h)	Body weight (g)	Mammary gland weight (g)
I	Control	37.40±1.36	0.316±0.560
II	24	36.30±1.68	0.283±0.640
III	48	35.70±2.12	0.237±0.350 ^a
IV	72	34.10±1.24 ^a	0.182±0.470 ^a
V	96	32.60±1.44 ^a	0.138±0.530 ^a

Values are mean±SEM of 5 animals. ^aSignificant $P \leq 0.05$ v.s. control.

3.2. Histopathology

Histopathological changes of lactating mammary gland tissue of mice inoculated with PBS, which served as control and *S. aureus* inoculum induced groups at the doses 0.8×10^1 , 1.4×10^2 , 2×10^2 and 2.8×10^3 CFU for 48 h are presented in Figure 1. The present histological observations of control mammary gland showed no polymorphonuclear neutrophils (PMN), leukocyte infiltrations, compactly arranged epithelial and luminal cells of healthy alveoli

filled with milk proteins, fat and lipid droplets as secretory products (Figure 1a). The mammary gland tissue of *S. aureus* inoculum induced groups caused massive PMN infiltrations and alveolar atrophy showing discontinuous epithelial and luminal cell lining and disturbed secretory products (Figure 1b–e). The aetiological symptoms were progressively observed as the CFU of *S. aureus* inoculum increased and prominently observed in 1.4×10^2 , 2×10^2 and 2.8×10^3 CFU induced groups, when compared with that of control.

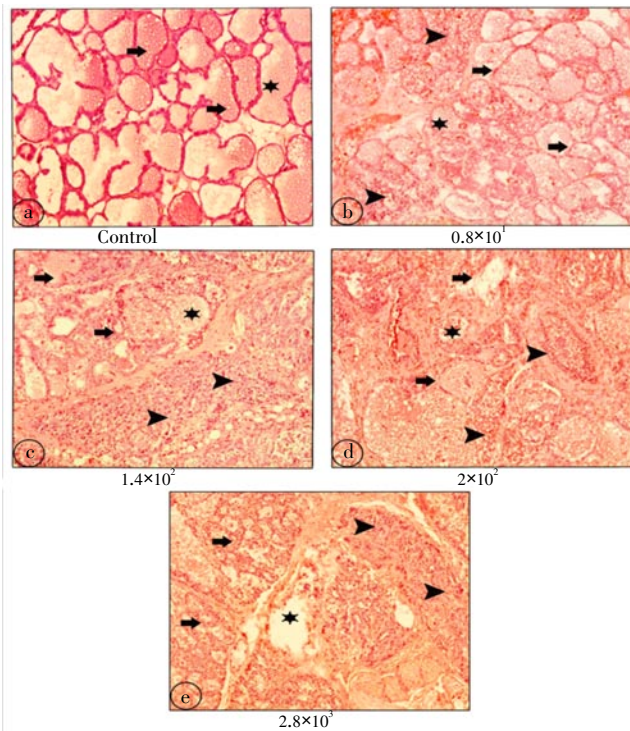


Figure 1. Histopathological changes of lactating mammary gland tissue of mice inoculated with PBS control and *S. aureus* inoculum induced groups at the doses 0.8×10^1 , 1.4×10^2 , 2×10^2 and 2.8×10^3 CFU for 48 h. Arrow represents alveoli, arrow head denotes PMN infiltration and star indicates secretory products. Magnifications 10 \times .

Histopathological changes of lactating mammary gland tissue of mice inoculated with PBS, which served as control, and *S. aureus* inoculum induced groups for durations of 24, 48, 72 and 96 h at 2×10^2 CFU are depicted in Figure 2. The present histological observations of control mammary gland showed no PMN's leukocyte infiltrations, intact epithelial and luminal cells of alveoli filled with healthy secretory products (Figure 2a). The mammary gland tissue of *S. aureus* inoculum induced groups produced massive PMN infiltrations, alveolar damage exhibited irregular epithelial and luminal cell lining and unstable secretory products (Figure 2b–e). The symptoms were increasingly witnessed as the duration of CFU of *S. aureus* inoculum increased and significantly observed in 48, 72 and 96 h induced groups, when

compared with that of control.

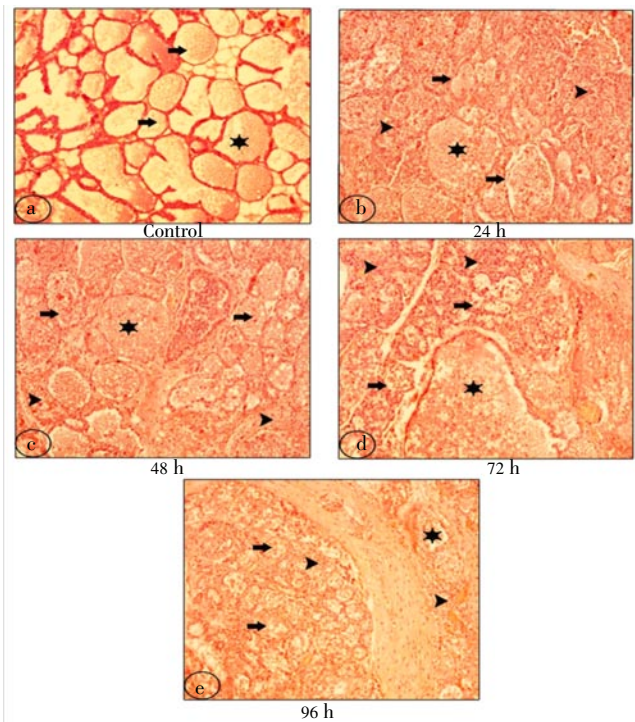


Figure 2. Histopathological changes of lactating mammary gland tissue of mice inoculated with PBS control and a dose of 2×10^2 CFU of *S. aureus* inoculum induced groups for durations 24, 48, 72 and 96 h of infection. Arrow represents alveoli, arrow head denotes polymorphonuclear neutrophil infiltration and star indicates secretory products. Magnifications 10 \times .

4. Discussion

Mastitis, the inflammation of the mammary gland, is characterized by the disruption of endothelial and epithelial integrity, the release of inflammatory mediators, and extensive neutrophil infiltration[15]. *S. aureus* is the major pathogen which infects the bovine udder causing severe clinical mastitis. The mouse model is used to study the host pathogen interaction of bovine mastitis disease by inducing the bacterial mastitis through intramammary inoculation of bacterial pathogens into the teat canal of the host mammary gland[16]. In the present study *S. aureus* inoculum dose of 5×10^4 CFU showed 50% mortality and first dilution of same dose showed 40% mortality at 24 h which may be due to severe pathophysiological infection, arresting the body systems and leading to the death. This inoculum dose became the basis to choose the minimal tissue inflammation dose of *S. aureus* inoculum strain to induce the intramammary infection for further studies. Akin results were reported with related clinical observations[13].

In the present study there was a significant decrease in body and mammary gland weight at dose 2×10^2 and 2.8×10^3 CFU for 48 h and at durations of 48, 72 and 96 h for 2×10^2 CFU induced groups respectively. Decrease in body and mammary gland weights of mice was observed as the dose and duration of *S. aureus* inoculum increased, which might

be due to the severe infection, progressive depression, weakness, and suppressed intake of the food. The bacterial load replicated rapidly and filled the alveolar space by PMN's leading to decrease in milk volume, milk energy, or mammary gland weight and tissue damage^[17]. Similar results were reported suggesting that the severity of mastitis may also progress to include systemic involvement such as fever, depression and loss of appetite which thereby results in decrease of body and mammary gland weights^[18]. Thus, intramammary bacterial infection decreased the body and mammary gland weights of mice.

In the present study histopathological evidences revealed massive infiltration of PMN leukocytes, the migration of PMN to the mammary gland tissue is due to the inflammation induced by *S. aureus* intramammary infection. Similar evidences were reported suggesting that infiltration by PMN in the mammary gland tissue is the hallmark of *S. aureus* mastitis^[13,17]. In the present study it was observed that PMN infiltration was significantly increased and evident both in 2×10^2 and 2.8×10^3 CFU induced groups, indicating dose pathogenicity and at 72 and 96 h induced groups and durational pathogenicity of the intramammary infection respectively. It may be due to that the presence of functional PMN is crucial to the host defense against bacterial pathogens but neutrophils may promote tissue injury and disturb mammary function, via reactive oxygen metabolite generation^[19]. Further, PMN accumulated in the alveolar space damaged secretory products such as milk proteins, lipid droplets and fats, which might be due to the loss of action of phagocytosis of bacteria by the PMN's leading to the tissue damage, were in accordance with earlier observations^[20].

In the present study the alveolar damage witnessed in the induced groups of both dose and durational experiments showed progressive, unstable and discontinuous linings of epithelial, luminal and myoepithelial cell destructions. Alveoli damage was significantly evident both in 2×10^2 and 2.8×10^3 CFU induced groups, indicating dose pathogenicity and at 72 and 96 h induced groups and durational pathogenicity of the intramammary infection respectively. The recent studies revealed the presence of toxin producing genes in the *S. aureus* isolated from milk of the cow with bovine mastitis^[21]. The alveolar damage may be due to toxins produced by *S. aureus* infection which destroy cell membranes, directly damaging milk-producing tissue. Cellular damage observed may be due to apoptosis or necrosis in tissue caused by migration of PMN to the mammary gland tissue attributing intramammary bacterial infection^[22,23]. Analogous results were observed in naturally infected and *S. aureus* induced mastitis of bovine mammary gland tissue^[24]. Similar results were also reported on experimentally induced mastitis by *S. aureus* in mice, suggesting that the tissue damage was initiated by intramammary bacterial infection^[17].

In the present study tissue injury causing alveolar destruction led to the decrease of secretory products such as milk proteins, lipid droplets and fat content due to the bacterial infection which act by rapidly dividing in the host by inhibiting the phagocytosis by PMN cells. Secretory

products significantly decreased both in 2×10^2 and 2.8×10^3 CFU induced groups, indicating dose pathogenicity and at 72 and 96 h induced groups and durational pathogenicity of the intramammary infection respectively. Similar inferences were reported suggesting that PMN accumulated in the alveolus reduced the secretion of milk products, thereby damaging alveoli and secretory products^[11,12]. Histopathological evidences were comparable with findings referred in the literature for the pathogenesis of *S. aureus* induced mastitis in mice^[14].

The present study results inferred that intramammary infection of *S. aureus* in mice damaged the mammary gland tissue. The increase in *S. aureus* inoculum doses and durations of infection increased the migration of quantity of PMN infiltration and intermittent quantity of virulence factors increased over time, leading to mammary gland tissue damage. The anatomical and cellular defense mechanisms of mammary gland weakened in function owing to the intramammary infection. Thus, histopathological changes and atrophies revealed that the tissue damage was due to increase in inoculum doses and durations of infection induced by *S. aureus*.

Conflict of interest statement

We declare that we have no conflict of interest.

Acknowledgements

The authors are grateful to the Department of Biotechnology, Ministry of Science and Technology, Government of India, New Delhi, for funding the Interdisciplinary Program for Life Science Project (BT/PR/4555/INF/22/126/2010 dated 30–09–2010). Bioinformatics Infrastructure Facility Project (BT/BI/25/001/2006 VOL II dt 05–03–2012) and P. G Departments of Microbiology and Biotechnology Karnatak University, Dharwad for providing the facilities.

Comments

Background

Worldwide, mastitis is one of the most important diseases in the dairy sector. The bovine mastitis caused by *S. aureus* has increased in many herds of urban and rural areas of the country. *S. aureus* constitute the majority of disease causing bacteria. It is known that the bacterial virulence proteins can influence the pathogenesis of the lesions. Mammary tissue damage has been shown to be induced by either apoptosis or necrosis. Both bacterial factors and host immune reactions contribute to epithelial tissue damage. During infection of the mammary glands, the tissue damage can initially be caused by bacteria and their products.

Research frontiers

In this paper the authors have made an attempt to

understand the histopathological changes of mouse mammary gland tissue damage when, induced by doses of *S. aureus* inoculum at increasing order of durations of infection.

Related reports

This study shows that the tissue injury causing alveolar destruction leads to significant decrease in secretory products such as milk proteins, lipid droplets and fat content due to the bacterial infection, which act by rapidly dividing in the host by inhibiting the phagocytosis by PMN cells. These findings are in line with Zhao and Lacasse (2008); Sordillo and Streicher (2002) suggesting PMN accumulated in the alveolus reduced the secretion of milk products, thereby damaging alveoli and secretory products.

Innovations & breakthroughs

Even though it is accepted that neutrophils, bacteria, host proteases and cytokines contribute to mammary tissue injury during mastitis, many finer details are still unidentified. This study adds information to the literature which helps to understand the pathogenesis mechanisms.

Applications

It may be important to know the changes in histopathology of mammary gland during dose and durational study. This study has showed that the increased dose and duration of *S. aureus* inoculum has significant effect of mammary tissues of mouse.

Peer review

The results are interesting and suggested that increased dose and duration of *S. aureus* inoculum has substantiated effect on mammary tissues of mouse. This is a good study in which the authors evaluated the histopathological changes of mammary gland induced by *S. aureus* in mice.

References

- [1] Sears PM, McCarthy KK. Management and treatment of staphylococcal mastitis. *Vet Clin North Am Food Anim Pract* 2003; **19**: 171–185.
- [2] Tenhagen BA, Hansen I, Reinecke A, Heuwieser W. Prevalence of pathogens in milk samples of dairy cows with clinical mastitis and in heifers at first parturition. *J Dairy Res* 2009; **76**: 179–187.
- [3] Myles IA, Datta SK. *Staphylococcus aureus*: an introduction. *Semin Immunopathol* 2012; **34**: 181–184.
- [4] Chandler RL. Ultrastructural pathology of mastitis in the mouse. *Br J Exp Pathol* 1970; **51**(6): 639–645.
- [5] Guo M, Zhang N, Li D, Liang D, Liu Z, Li F, et al. Baicalin plays an anti-inflammatory role through reducing nuclear factor- κ B and p38 phosphorylation in *S. aureus*-induced mastitis. *Int Immunopharmacol* 2013; **16**: 125–130.
- [6] Li D, Fu Y, Zhang W, Su G, Liu B, Guo M, et al. Salidroside attenuates inflammatory responses by suppressing nuclear factor- κ B and mitogen activated protein kinases activation in lipopolysaccharide-induced mastitis in mice. *Inflamm Res* 2013; **62**: 9–15.
- [7] Chen H, Mo X, Yu J, Huang Z. Alpinetin attenuates inflammatory responses by interfering toll-like receptor 4/nuclear factor kappa B signaling pathway in lipopolysaccharide-induced mastitis in mice. *Int Immunopharmacol* 2013; **17**: 26–32.
- [8] Demon D, Ludwig C, Breyne K, Guédé D, Dörner JC, Froyman R, et al. The intramammary efficacy of first generation cephalosporins against *Staphylococcus aureus* mastitis in mice. *Vet Microbiol* 2012; **160**: 141–150.
- [9] Leitner G, Pinchasov Y, Morag E, Spanier Y, Jacoby S, Eliau D, et al. Immunotherapy of mastitis. *Vet Immunol Immunopathol* 2013; **153**: 209–216.
- [10] Plastringe WN. Bovine mastitis: a review. *J Dairy Sci* 1958; **41**: 1141–1181.
- [11] Zhao X, Lacasse P. Mammary tissue damage during bovine mastitis: causes and control. *J Anim Sci* 2008; **86**: 57–65.
- [12] Sordillo LM, Streicher KL. Mammary gland immunity and mastitis susceptibility. *J Mammary Gland Biol Neoplasia* 2002; **7**: 135–146.
- [13] Brouillette E, Grondin G, Lefebvre C, Talbot BG, Malouin F. Mouse mastitis model of infection for antimicrobial compound efficacy studies against intracellular and extracellular forms of *Staphylococcus aureus*. *Vet Microbiol* 2004; **101**: 253–262.
- [14] Brouillette E, Malouin F. The pathogenesis and control of *Staphylococcus aureus* induced mastitis: study models in the mouse. *Microbes Infect* 2005; **7**: 560–568.
- [15] Bradley A. Bovine mastitis: an evolving disease. *Vet J* 2002; **164**: 116–128.
- [16] Notebaert S, Meyer E. Mouse models to study the pathogenesis and control of bovine mastitis. A review. *Vet Q* 2006; **28**: 2–13.
- [17] Brouillette E, Grondin G, Talbot BG, Malouin F. Inflammatory cell infiltration as an indicator of *Staphylococcus aureus* infection and therapeutic efficacy in experimental mouse mastitis. *Vet Immunol Immunopathol* 2005; **104**: 163–169.
- [18] Sordillo LM. New concepts in the causes and control of mastitis. *J Mammary Gland Biol Neoplasia* 2011; **16**: 271–273.
- [19] Paape MJ, Bannerman DD, Zhao X, Lee JW. The bovine neutrophil: structure and function in blood and milk. *Vet Res* 2003; **34**: 597–627.
- [20] Capuco AV, Ellis SE, Hale SA, Long E, Erdman RA, Zhao X, et al. Lactation persistency: insights from mammary cell proliferation studies. *J Anim Sci* 2003; **81**: 18–31.
- [21] Akineden O, Annemüller C, Hassan AA, Lämmler C, Wolter W, Zschöck M. Toxin genes and other characteristics of *Staphylococcus aureus* isolates from milk of cows with mastitis. *Clin Diagn Lab Immunol* 2001; **8**: 959–964.
- [22] Akers RM, Nickerson. Mastitis and its impact on structure and function in the ruminant mammary gland. *J Mammary Gland Biol Neoplasia* 2011; **16**: 275–289.
- [23] Yu JJ, Bao SL, Yu SL, Zhang DQ, Loo WT, Chow LW, et al. Mouse model of plasma cell mastitis. *J Transl Med* 2012; **10**: S11.
- [24] Lasagno MC, Vissio C, Reinoso EB, Raspanti C, Yaciuk R, Larriestra AJ, et al. Development of an experimentally induced *Streptococcus uberis* subclinical mastitis in goats. *Vet Microbiol* 2012; **154**: 376–383.