

Contents lists available at [ScienceDirect](http://www.sciencedirect.com)

## Asian Pacific Journal of Tropical Disease

journal homepage: [www.elsevier.com/locate/apjtd](http://www.elsevier.com/locate/apjtd)

Case report doi: 10.1016/S2222-1808(15)60841-6

©2015 by the Asian Pacific Journal of Tropical Disease. All rights reserved.

## Bilateral idiopathic optic perineuritis with severe vision loss: A case report

Wee-Min Teh\*, Mohtar Ibrahim, Wan-Hazabbah Wan Hitam

Department of Ophthalmology, School of Medical Sciences, Health Campus, Universiti Sains Malaysia, 16150 Kubang Kerian, Kelantan, Malaysia

## ARTICLE INFO

## Article history:

Received 14 Oct 2014

Received in revised form 27 Oct 2014

Accepted 5 Nov 2014

Available online 2 May 2015

## Keywords:

Optic perineuritis

Idiopathic orbital inflammatory disease

Visual loss

## ABSTRACT

Optic perineuritis is an orbital inflammatory disorder that is either idiopathic or secondary to other conditions such as infection or systemic inflammatory disorders. This condition is very similar to demyelinating optic neuritis, but certain features of the history and magnetic resonance imaging findings are characteristic for and aid in the diagnosis of optic perineuritis. Vision loss varies greatly, from minimal clouding of vision up to only light perception. We report a case of a 44-year-old female with idiopathic bilateral optic perineuritis with vision loss of up to no light perception in both eyes. Radio imaging studies were typical of optic perineuritis and she was started on systemic corticosteroids. She responded very well to steroid therapy and achieved nearly complete visual recovery. There had been no relapse despite cessation of therapy.

## 1. Introduction

Optic perineuritis (OPN) is part of a larger group of orbital inflammatory disorders involving the optic nerve sheath that may occur in acute or subacute forms and can progress further to chronic disease[1]. While the majority of OPN cases are of unknown aetiology, it can also be due to certain infections such as tuberculosis[2] or syphilis[3], or as manifestation of a systemic inflammatory disorder such as sarcoidosis or Wegener's granulomatosis[4].

The clinical features of OPN vary greatly, with decreased vision and pain on eye movements being the commonest symptoms. Other symptoms include double vision, visual field defects, proptosis or ptosis and conjunctival injection. There have been reports of visual loss of up to no light perception which are

usually unilateral and secondary to an underlying aetiology. We would like to report a case of bilateral idiopathic OPN with severe visual loss of up to no light perception in both eyes that achieved almost complete recovery after initiating systemic corticosteroid therapy.

## 2. Case report

A 44-year-old Malay female schoolteacher presented with sudden onset of reduced vision in both eyes that progressively worsened over three days. She noticed this upon waking up in the morning, initially describing her vision as if there was something obscuring it. Her vision worsened in the three days to the extent that she was unable to ambulate without assistance as she would knock things over while walking unaided. It was at this point that she sought an ophthalmic consultation. There was no preceding floaters or flashes and her vision did not deteriorate with heat or exercise. She had mild headache and pain on eye movements, especially on upward and inward gaze. There was no upper respiratory symptoms or those suggestive of raised intracranial pressure. There was also no weakness or numbness

\*Corresponding author: Wee-Min Teh, Postgraduate Trainee, Department of Ophthalmology, School of Medical Sciences, Health Campus Universiti Sains Malaysia, 16150 Kubang Kerian, Kelantan, Malaysia.

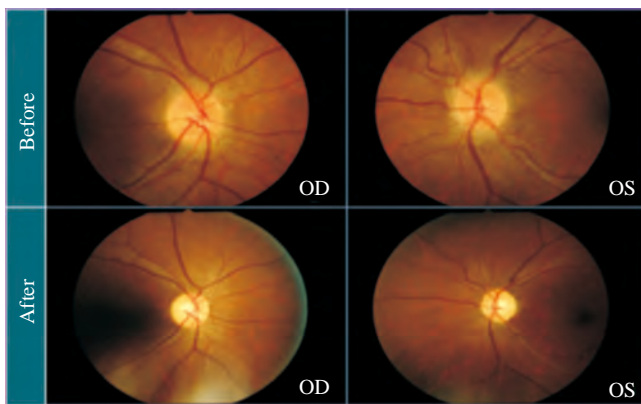
Tel: (+60)12-2543415

E-mail: [tehweemin@yahoo.com](mailto:tehweemin@yahoo.com)

Foundation Project: Supported by a Short Term University Grant from University Sains Malaysia (Grant No. 304/PPSP/61313097).

felt. She denied any symptoms or any close contact with persons affected by tuberculosis. There was no recent exposure to any toxins or immunisation and she was not on any supplements. She also denied any high-risk behaviour.

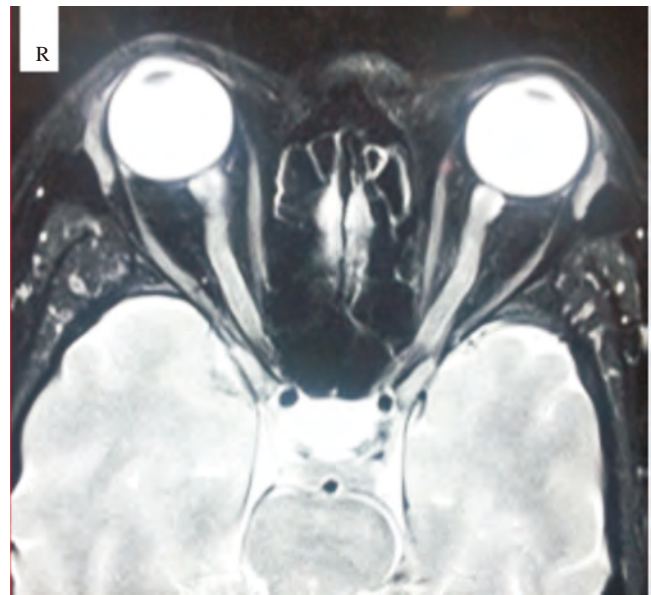On examination, initial visual acuity was 6/36 (right eye) and light perception (left eye). There was significant reduction in brightness and contrast sensitivity, and confrontational field testing of the right eye showed constriction of peripheral vision. Red desaturation was also elicited in the right eye (left eye testing was not possible due to the severe visual loss). Extraocular muscle movements were normal, with mild discomfort described by the patient on adduction and elevation. Anterior segment examination was unremarkable, except for a positive relative afferent pupillary defect elicited in the left eye despite both pupils reacting sluggishly. Both optic discs were swollen and hyperaemic (Figure 1). There was no retinitis or vitritis. No other neurological deficit was elicited on examination. Lhermitte's sign was negative and the neck was not stiff. There were no other signs of meningeal irritation. Systemic examination was unremarkable except for mild pallor noted.



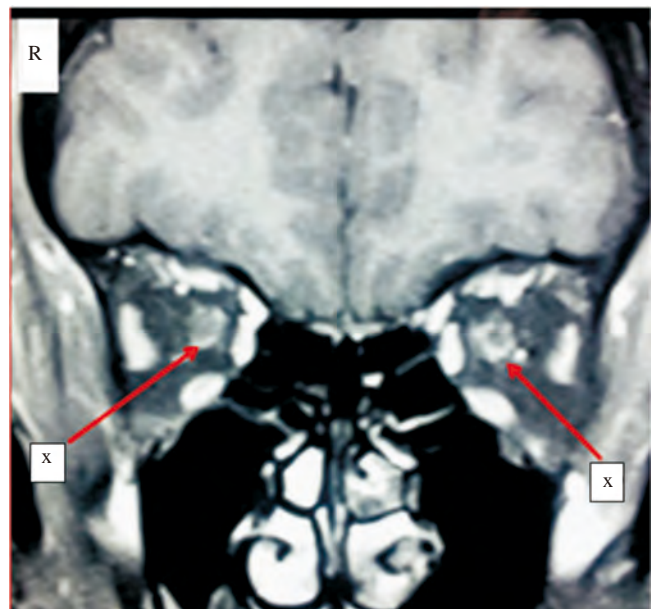
**Figure 1.** Fundus photographs showing the swollen and hyperaemic optic discs on initial presentation before commencement of corticosteroids and their resolution after 10 weeks.

OD: Right eye; OS: Left eye.

An urgent computed tomography scan of the brain which was performed to rule out any intracranial mass proved normal, while blood investigations for infective and connective tissue screening (erythrocyte sedimentation rate, venereal disease research laboratory, C<sub>3</sub>, C<sub>4</sub>, anti-nuclear antibody, anti-dsDNA and rheumatoid factor) were negative. She had incidental finding of hypochromic microcytic anaemia with low plasma ferritin but normal iron-binding capacity suggestive of iron deficiency anaemia. Magnetic resonance imaging (MRI) of the brain showed patchy enhancement of the posterior aspect of bilateral intraconal optic nerve sheaths (Figure 2). The classical “doughnut sign” of the signal-enhancing optic nerve sheath was seen in both eyes on coronal views (Figure 3). There was no abnormal intracranial white matter enhancement of the brain parenchyma.



**Figure 2.** MRI orbits (T2-weighted axial view) showing patchy enhancements of both optic nerve sheaths and slight thickening especially at the retrobulbar portion.



**Figure 3.** MRI orbits (T2-weighted coronal view) showing the classical “doughnut sign”.

x: Signal enhancement of the optic nerve sheaths.

A diagnosis of bilateral idiopathic OPN was made. After consultation with a neuro-ophthalmologist, intravenous infusion of methylprednisolone at 250 mg *quater in die* was initiated for three days. Initially, vision deteriorated further to no perception of light in both eyes despite commencing intravenous methylprednisolone for 12 doses. Nevertheless, steroids continued to be given in the form of oral prednisolone at 1 mg/kg/day. Vision only gradually improved after about 2 weeks of steroid therapy, which was then tapered off gradually every 2 weeks.

On follow-up at about 10 weeks after initial presentation, her optic discs swelling had subsided with clear disc margins, but

there was mild temporal pallor in both discs. Her best corrected visual acuity had improved to 6/6 (right eye) and 6/9 (left eye). Humphrey perimetric testing showed paracentral depression in the left eye and mild patchy scotoma in the right. Oral prednisone was tapered off after 12 weeks of therapy. To date, there has been no recurrence of similar episodes after almost a year of follow-up and her vision remained good.

### 3. Discussion

OPN is an inflammation of the optic nerve sheath which can be due to infective and non-infective causes. First described by Edmunds and Lawford in 1883[5], the commonest cause of OPN is secondary syphilitic infection, followed by inflammatory disorders such as sarcoidosis, Wegener's granulomatosis and idiopathic orbital inflammatory disease. There has also been a reported case of OPN and encephalomyelitis occurring as sequelae of influenza vaccination[6]. In our patients, the aetiology was likely a spectrum of idiopathic orbital inflammatory disease as the various blood and immunological tests done were negative, and the patient responded well with systemic steroids.

Clinically, OPN is often mistaken for acute demyelinating optic neuritis as the clinical presentation and ophthalmic findings are very similar. In both these disorders, patients typically present with sudden onset of decreased visual acuity and colour vision, pain on eye movements and either a normal or swollen optic disc upon fundus examination. There are, however, features which may help the treating physician in differentiating the two conditions[7]. Among the features that are suggestive of OPN include a generally broader range of age of onset, paracentral or arcuate visual field defects, gradual progression of visual loss, prompt and dramatic response to corticosteroids, and characteristic MRI scan findings[8]. MRI scans of the optic nerves in OPN typically demonstrate a "tramtrack" appearance on axial views and "doughnut" sign on the coronal plane. The characteristic MRI findings in our patient helped us to clinch the diagnosis of OPN and steroid therapy was started and maintained for a longer duration.

Another distinctive feature of OPN is its good response to steroid therapy. The treatment regime for steroids varies greatly, with some physicians opting for intravenous or oral steroids at a dose usually ranging from 0.5 to 1 mg/kg/day. Steroid therapy is frequently given at a tapering dose over many months due to the risk of relapse in OPN. The prognosis is often much poorer if there has been a delay in the initiation of treatment. Nevertheless, there have been cases of good recovery of OPN with corticosteroids even after there was long interval between onset of symptoms and the initiation of treatment of more than six

months[9]. Our patients have fortunately not suffered a recurrence since the first episode and she remained free from any further steroid therapy.

The degree of visual loss during initial presentation of OPN varies greatly; some may have 20/20 visual acuity but still present with visual disturbance such as clouding of vision in certain patches, while others have presented with vision of light perception only. Bilateral involvement is also uncommon, with most reports of bilateral OPN occurring in patients with secondary causes such as syphilitic infection. We believe that our patients are the first reported case of bilateral idiopathic OPN with severe vision loss of up to no light perception, which responded dramatically well to systemic steroids and regained almost normal visual acuity.

### Acknowledgments

This publication is supported by a Short Term University Grant from University Sains Malaysia (Grant No. 304/PPSP/61313097).

### Conflict of interest statement

We declare that we have no conflict of interest.

### References

- [1] Ding ZX, Lip G, Chong V. Idiopathic orbital pseudotumour. *Clin Radiol* 2011; **66**(9): 886-92.
- [2] Raghbi A, Hitam WHW, Noor RAM, Embong Z. Optic perineuritis secondary to tuberculosis: a rare case presentation. *Asian Pac J Trop Biomed* 2012; **2**(2): S1206-8.
- [3] Meehan K, Rodman J. Ocular perineuritis secondary to neurosyphilis. *Optom Vis Sci* 2010; **87**(10): E790-6.
- [4] Purvin V, Kawasaki A. Optic perineuritis secondary to Wegener's granulomatosis. *Clin Experiment Ophthalmol* 2009; **37**: 712-7.
- [5] Edmunds W, Lawford JB. Examination of optic nerves from cases of amblyopia in diabetes. *Trans Ophthalmol Soc UK* 1883; **3**: 160-2.
- [6] Vilain S, Waterschoot MP, Mavroudakos N. Encephalomyelitis and bilateral optic perineuritis after influenza vaccination. *Bull Soc Belge Ophthalmol* 2000; (277): 71-3.
- [7] Lai C, Tian G, Liu W, Wei W, Takahashi T, Zhang X. Clinical characteristics, therapeutic outcomes of isolated atypical optic neuritis in China. *J Neurol Sci* 2011; **305**(1-2): 38-40.
- [8] Purvin V, Kawasaki A, Jacobson DM. Optic perineuritis: clinical and radiographic features. *Arch Ophthalmol* 2001; **119**: 1299-306.
- [9] Tatsugawa M, Noma H, Mimura T, Funatsu H. High-dose steroid therapy for idiopathic optic perineuritis: a case series. *J Med Case Rep* 2010; **4**: 404.