

Contents lists available at [ScienceDirect](#)

Asian Pacific Journal of Tropical Disease

journal homepage: www.elsevier.com/locate/apjtd

Case report

doi: 10.1016/S2222-1808(15)60926-4

©2015 by the Asian Pacific Journal of Tropical Disease. All rights reserved.

Severe tuberculous retinal vasculitis in healthy adults

Sin Yee Fang, Norshamsiah Md Din, Hazlita Isa, Hon Seng Wong*

Department of Ophthalmology, Universiti Kebangsaan Malaysia, Jalan Yaacob Latiff, Kuala Lumpur, Malaysia

ARTICLE INFO

Article history:

Received 3 Jun 2015

Received in revised form 15 Jun 2015

Accepted 25 Jun 2015

Available online 17 Jul 2015

Keywords:

Ocular tuberculosis

Retinal vasculitis

Healthy

Pan-retinal photocoagulation

ABSTRACT

Ocular tuberculosis may be a presenting feature of tuberculous infection, especially with extensive occlusive retinal vasculitis among Asians. Being a curable disease, awareness of its presentation and high index of suspicion are paramount as prompt treatment can halt the disease progression and prevent visual loss. We presented three cases of ocular tuberculosis in young healthy adults who presented with progressive blurring of vision with florid retinal vasculitis seen on funduscopy. Two of them were with no bacillus Calmette-Guerin scar. Fundus fluorescein angiography confirmed the presence of occlusive vasculitis with extensive area of ischemia. All cases showed a raise in erythrocyte sedimentation rate and strongly positive Mantoux tests. Pan-retinal photocoagulation was given to all patients. Two cases responded well to anti-tubercular therapy followed by oral steroids and regained normal vision in both eyes. One patient was not started on anti-tubercular therapy as he requested to return to his native country for further treatment.

1. Introduction

Tuberculosis (TB) is among the top 5 transmissible diseases in Malaysia and the incidence of TB in Malaysia shows an increasing trend in the last decade[1]. It is a curable infectious disease caused by the acid-fast bacillus *Mycobacterium tuberculosis*. TB is spread through air-droplets, when infected individuals cough or sneeze. The World Health Organization estimated that one-third of the world population is infected with *Mycobacterium tuberculosis* and 10% of infected people have a lifetime risk of manifesting tuberculous disease[2].

Eye involvement is an uncommon presentation of extrapulmonary TB, seen in approximately 2.8%–11.4% of patients[3]. Retinal vasculitis is the commonest manifestation of intraocular TB[4]. TB mostly affects young adults especially immunocompromised individuals due to diabetes mellitus, malnutrition, HIV infection and

tobacco smokers[2]. Ocular TB, as the presenting manifestation of extrapulmonary TB in young healthy adults, is however uncommon.

We report three cases of healthy young adults with ocular signs and symptoms as the first presenting features of intraocular TB.

2. Cases report

2.1. Case 1

A 17-year-old healthy male of Indonesian parentage, presented with 1 week history of bilateral painless progressive blurring of vision. He had no prolonged fever, cough, night sweats or recent loss of weight. There was no history of exposure to TB patients. His visual acuity was counting fingers in the right eye (OD) and 6/36 in the left eye (OS). There were anterior chamber cells of 2+ with granulomatous keratic precipitates both eyes (OU). Funduscopy revealed an infero-temporal branch retinal vein occlusion with a partial macular star exudation OD (Figure 1A). Both fundi showed extensive retinal vasculitis with periphlebitis and intra-retinal hemorrhages (Figure 1A, B). Fundus fluorescein angiogram (FFA) showed extensive capillary fall out and leaking new vessels (Figure

*Corresponding author: Hon Seng Wong, Department of Ophthalmology, Pusat Perubatan Universiti Kebangsaan Malaysia, Jalan Yaacob Latiff, Bandar Tun Razak, Cheras, 56000 Kuala Lumpur, Malaysia.

Tel: +603-91455981, 5982/5998

Fax: +603-91456673

E-mail: whonseng@gmail.com

1C). Systemic examinations were normal but a bacillus Calmette-Guerin (BCG) scar was absent. The chest X-ray was normal but his Mantoux test was 21 mm of erythematous induration and erythrocyte sedimentation rate (ESR) was 97 mm/h. Other uveitis workups were normal and retroviral screening was negative. This patient was started on anti-tubercular therapy (ATT) with systemic corticosteroid and bilateral panretinal photocoagulation (PRP) was performed. The retinal vasculitis responded well to the treatment and the patient regained 6/6 vision in OU after 3 months.

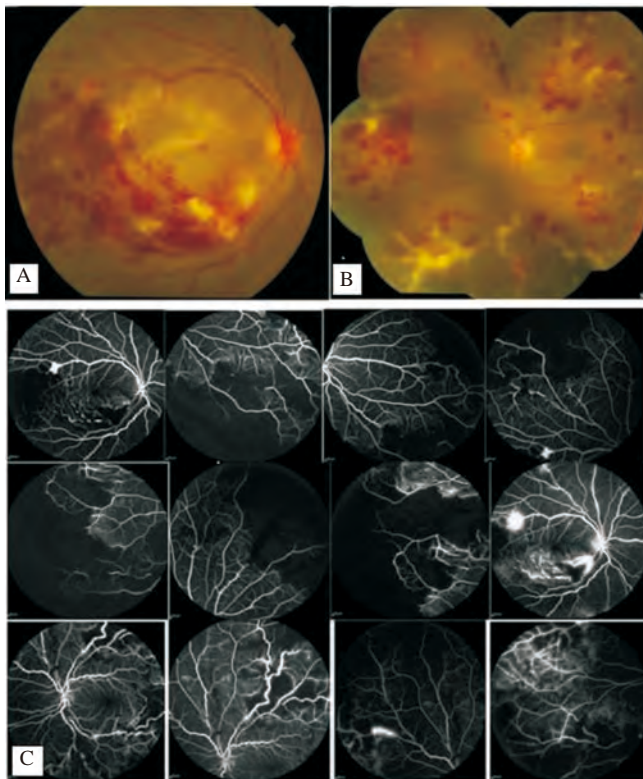


Figure 1. Fundus photograph and fundus fluorescein angiography of case 1. A: Right eye infero-temporal branch retinal vein occlusion with a partial macular star exudation; B: Left eye extensive vasculitis with periphlebitis and intra-retinal hemorrhages; C: Fundus fluorescein angiography showed extensive capillary fall-out, vasculitis and leaking new vessels.

2.2. Case 2

An 18-year-old healthy Chinese girl presented with left progressive blurring of vision for 11 days. She had no history of contact with TB patient. Visual acuity was 2/60 OS and 6/9 OD. Anterior segment examination was normal bilaterally. Fundi examinations showed bilateral vitritis of about 4+, with retinal vasculitis and vitreous haemorrhage OS (Figure 2A, B). FFA showed peripheral vasculitis with large area of capillary fall-out (OS > OD), and new vessels OS (Figure 2C). She had a BCG scar and the chest X-ray was normal. The Mantoux test was 25 mm and ESR was 48 mm/h. Retroviral screening and other workup was negative. She was started on ATT with systemic steroid and given PRP in OU. She responded well to treatment and vision OU recovered to 6/6 within 1 month.

Subsequently in the following 9 months she developed recurrent episodes of spontaneous vitreous haemorrhage OS which ultimately resolved without requiring pars plana vitrectomy. Visual acuity OU has since remained stable at 6/6 after 2 years.

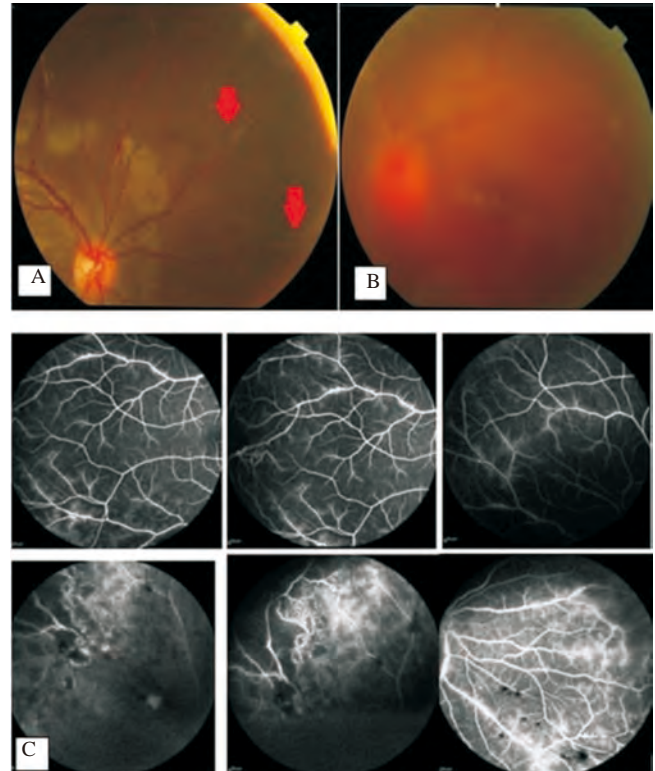


Figure 2. Fundus photograph and fundus fluorescein angiography of case 2. A: Right eye vasculitis; B: Left eye vitreous hemorrhage; C: Fundus fluorescein angiography showed peripheral vasculitis with large area of CFOs and new vessels in the OS.

2.3. Case 3

A 24-year-old Burmese male, who worked in Malaysia for the last 2 years without known medical illness, presented with a 2-month history of painless progressive loss of vision OS, preceded with floaters. There was no history of recent contact with TB patient, chronic cough, fever, night sweats or recent weight loss. No BCG scar was seen in this patient. His visual acuity was 6/6 OD and hand movement OS. Left relative afferent pupillary defect was presented. There was no anterior uveitis seen. Dilated fundi examination revealed perivascular sheathing with telangiectatic vessels OD (Figure 3A) and vitreous haemorrhage with localised area of tractional retinal detachment OS (Figure 3B). FFA showed extensive area of periphery capillary fall-out and leakage OD (Figure 3C). Mantoux test was highly positive with reading of 45 mm and ERS was 67 mm/h. The chest X-ray showed clear lung fields. Retroviral screening and other workup was negative. The OD was treated with complete PRP. However, ATT treatment was not started as patient returned to Myanmar for continuation of treatment.

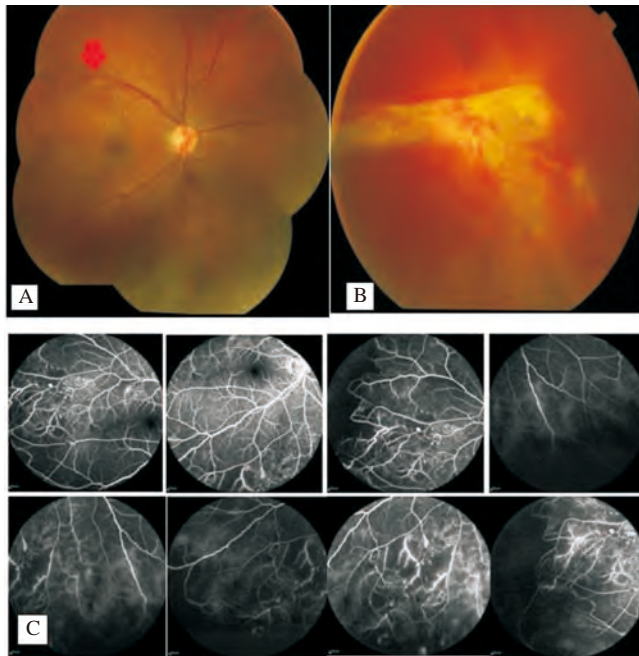


Figure 3. Fundus photograph and fundus fluorescein angiography of case 3. A: Right eye perivascular sheathing with telangiectatic vessels; B: Left eye vitreous hemorrhage with localised area of tractional retinal detachment; C: Fundus fluorescein angiography showed OD extensive area of periphery capillary fall-out and leakage.

3. Discussion

The overall cases of notified TB have shown an increasing trend in Malaysia from the year 2000 to 2012[1] despite a decline in the incidence of TB in developed countries during the last century[2]. The three cases we reported here are healthy young adults with age ranging from 17 to 24 years. Two of the patients are immigrants without BCG vaccination, potentially being at a greater risk of developing active TB[5].

It is postulated that ocular TB occurs as a result of direct haematogenous spread after a primary infection or by hypersensitivity response[6]. All three patients reported here fall into the category of presumed ocular TB without evidence of active systemic disease or definitive microbial detection. All of them demonstrated ocular symptoms as the first presenting feature of TB. The definitive diagnosis by direct evidence of ocular infection is often difficult and impractical. Tuberculous retinal vasculitis should be suspected when healthy young adult of Asian origin presents with retinal vasculitis and extensive capillary fall-out with a mild degree of vitreous cells[6], as seen in all three cases. Case 1 highlighted the rare presentation of retinal vein occlusion secondary to tuberculous retinal vasculitis[7]. It is postulated that the antibody-antigen complex reaction leads to hypersensitivity-like responses, resulted in occlusion of blood vessels, predominantly the retinal veins. Neovascularization may complicate the large area of capillary fall-out leading to vitreous haemorrhage (case 2 and case 3) and PRP has been shown to be successful in treating and preventing this complication[6,8].

The three reported cases here had no overt active pulmonary TB. The diagnosis of intraocular TB was supported by the strongly positive

Mantoux test which is relatively specific[9], and a raised ESR. The chest X-ray should routinely be performed although it may be normal as in our cases. As shown in case 1 and case 3, Mantoux test remains a highly specific and reliable test in patients without BCG vaccination[10].

Reactivation of systemic illnesses leading to military TB can occur if the retinal vasculitis treated with oral steroid alone. ATT should be started in these patients for the control of systemic disease before the initiation of oral steroid. Vitreous haemorrhage and neovascularization with retinal vasculitis and capillary fall-out responded well to PRP laser as demonstrated by case 1 and case 2.

These cases showed that extensive retinal vasculitis can be the presenting features of TB in young and healthy individuals. A high index of suspicion is essential, especially if BCG vaccination was not given in patients from prevalent countries for TB. TB is a curable disease, hence the awareness of its presentation and prompt treatment can halt the disease progression and prevent visual loss.

Conflict of interest statement

We declare that we have no conflict of interest.

References

- [1] Ministry of Health, Academy of Medicine Malaysia, Malaysian Thoracic Society. *Clinical practice guidelines management of tuberculosis*. 3rd ed. Putrajaya: Malaysia Health Technology Assessment Section; 2012.
- [2] World Health Organization. *Tuberculosis*. Geneva: World Health Organization; 2015. [Online] Available from: <http://www.who.int/mediacentre/factsheets/fs104/en/> [Accessed on 14th April, 2015]
- [3] Sharma A, Thapa B, Lavaju P. Ocular tuberculosis: an update. *Nepal J Ophthalmol* 2011; **3**(1): 52-67.
- [4] Manousaridis K, Ong E, Stenton C, Gupta R, Browning AC, Pandit R. Clinical presentation, treatment, and outcomes in presumed intraocular tuberculosis: experience from Newcastle upon Tyne, UK. *Eye (Lond)* 2013; **27**(4): 480-6.
- [5] Roy A, Eisenhut M, Harris RJ, Rodrigues LC, Sridhar S, Habermann S, et al. Effect of BCG vaccination against *Mycobacterium tuberculosis* infection in children: systematic review and meta-analysis. *BMJ* 2014; **349**: g4643.
- [6] Rosen PH, Spalton DJ, Graham EM. Intraocular tuberculosis. *Eye (Lond)* 1990; **4**(Pt 3): 486-92.
- [7] Fountain JA, Werner RB. Tuberculous retinal vasculitis. *Retina* 1984; **4**: 48-50.
- [8] Gur S, Siverstone BZ, Zylberman R, Berson D. Chorioretinitis and extrapulmonary tuberculosis. *Ann Ophthalmol* 1987; **19**: 112-5.
- [9] Lee JE, Kim HJ, Lee SW. The clinical utility of tuberculin skin test and interferon- γ release assay in the diagnosis of active tuberculosis among young adults: a prospective observational study. *BMC Infect Dis* 2011; **11**: 96.
- [10] Glassroth J, Robins AG, Snider DE Jr. Tuberculosis in the 1980s. *N Eng J Med* 1980; **302**: 1441-50.