


Contents lists available at [ScienceDirect](http://ScienceDirect.com)

Asian Pacific Journal of Tropical Disease

journal homepage: www.elsevier.com/locate/apjtd

Case report doi: 10.1016/S2222-1808(15)60883-0

©2015 by the Asian Pacific Journal of Tropical Disease. All rights reserved.

Hepatosplenic candidiasis in patient with acute leukemia

Habip Gedik^{1*}, Osman Yokuş²¹Department of Infectious Diseases and Clinical Microbiology, Ministry of Health Bakırköy Sadi Konuk Training and Research Hospital, İstanbul, Turkey²Department of Hematology, Ministry of Health İstanbul Training and Research Hospital, İstanbul, Turkey

ARTICLE INFO

Article history:

Received 9 Jan 2015

Received in revised form 19 Jan, 2nd revised form 20 Jan, 3rd revised form 10 Mar 2015

Accepted 10 May 2015

Available online 4 Jun 2015

Keywords:

Hepatosplenic candidiasis

Acute leukemia

Neutropenia

ABSTRACT

Hepatosplenic candidiasis (HSC) is a disseminated invasive fungal infection that commonly occurs in patients with acute leukemia. Persistent fever in patients who recovered from prolonged neutropenia subsequent to chemotherapy is the main symptom. A case is presented of a 26 year-old man, who was admitted to Hematology Ward with acute T-cell lymphoblastic leukemia. Febrile neutropenia developed after two cycles of hyper CVAD 1 and two cycles of hyper CVAD 2 chemotherapy. HSC was diagnosed and confirmed by computed axial tomography and hepatic biopsy. A persistent fever under antibiotic therapy should prompt investigation of HSC or other invasive fungal infection in immunocompromised patients.

1. Introduction

Candida associated invasive fungal infection commonly involves the liver and the spleen in immunocompromised patients. Hepatosplenic candidiasis (HSC) is a disseminated invasive fungal infection that commonly occurs in patients with acute leukemia. Persistent fever in patients who recovered from prolonged neutropenia subsequent to chemotherapy is main symptom[1]. HSC is substantially diagnosed with prolonged fever, elevated serum bilirubin and alkaline phosphatase values, radiologic findings obtained by computed tomography, nuclear magnetic resonance and ultrasonographic (and occasionally PET-CT) findings, and positive blood culture[2-4].

Hereby, a case with HSC has been reported after prolonged neutropenia episodes that developed subsequent to chemotherapy for acute leukemia.

2. Case report

A 26 year-old man had been admitted to the Hematology Ward due to acute T-cell lymphoblastic leukemia (ATLL) and received two cycles of hyper CVAD 1 and two cycles of hyper CVAD 2 chemotherapy. Neutropenia developed during the third cycle of chemotherapy and lasted 15 days. The patient had been treated with empirical antibacterial therapy (Cefoperazone-sulbactam 2 g/tid). Although neutrophil count increased, fever persisted with a temperature of 38-39 °C and elevated serum alkaline phosphatases (ALP) and gamma glutamyl transferase (GGT). The HSC diagnosis was strongly suggested by abdominal ultrasonography (USG), CT and MRI that showed multiple hypodense lesions in the liver and spleen consistent

*Corresponding author: Habip Gedik, Infectious Diseases and Clinical Microbiology Physician, Department of Infectious Diseases and Clinical Microbiology, Ministry of Health Bakırköy Sadi Konuk Training and Research Hospital, İstanbul, Turkey.

Tel: +90 212 314 55 55

Fax: +90 212 221 78 00

E-mail: habipgedik@yahoo.com

with hepatosplenic microabscesses (Figures 1 and 2). Positron emission tomography–computed tomography (PET-CT) revealed focal increased FDG uptake indicating the involvement of liver (mild hypermetabolic view, SUV max: 4) (Figure 3). Diffuse heterogeneous hypermetabolic activity in the spleen (diffusely increased FDG uptake compared to the liver, SUV max: 2.5) and diffuse increased bone marrow involvement in the skeletal system (SUV max: 5) had been also reported. Samples had been taken from the liver by CT imagination for pathologic examination. However, the sample had been reported to be insufficient for diagnosis. HSC had been confirmed by serologic tests that indicate the presence of circulating *Candida* antigens. HSC presented with persistent fever after recovering of neutropenia. The diagnosis had been confirmed with fine needle biopsy that was performed to hepatic lesions by USG. The causative agent had been identified by polymerase chain reaction (PCR) as *Candida albicans*. The patient was treated with amphotericin B for 5 days, followed by caspofungin therapy due to allergic reaction to amphotericin B for 10 days and then voriconazole as oral therapy for 3 months. The patient's fever and elevated serum alkaline phosphatase and gamma glutamic transferase values recovered. PET-CT and MRI that had been performed two months after treatment showed decreases in the size and number of lesions in the liver and spleen.

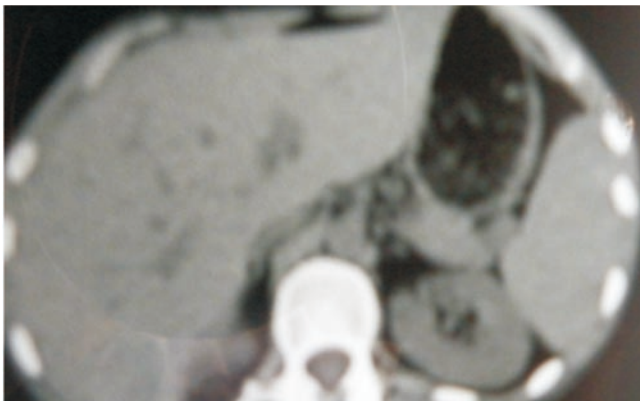


Figure 1. During fever and neutropenia upper abdominal MR showing multiple liver and splenic cystic lesions.

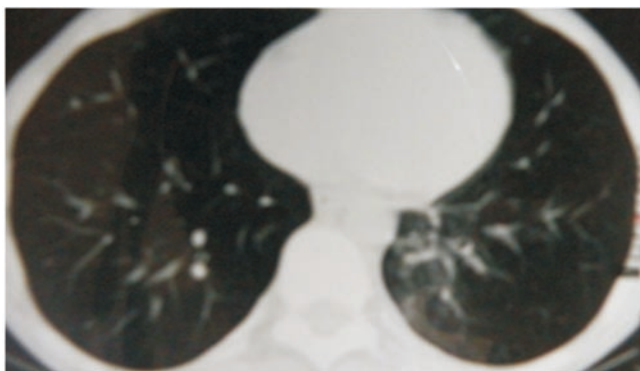
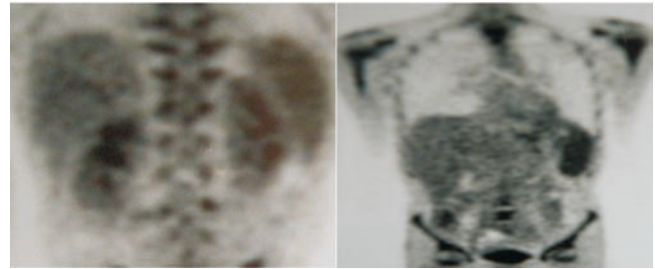


Figure 2. Thorax CT showing reticulonodular infiltration of basal lung fields.



Figures 3. PET-CT: liver 7th segment showing increased focal FDG uptake (SUV max: 4) suggestive of metastasis of primary disease; slightly hypermetabolic view. Heterogeneous character and appearance of diffuse hypermetabolic spleen (SUVmax: 2.5) (involvement of primary disease). Diffuse skeletal system and bone marrow indicate increased hypermetabolic activity (SUV max: 5).

3. Discussion

Chronic disseminated candidiasis (mainly its hepatosplenic form) is a clinical manifestation of invasive fungal infections due to *Candida* spp. in hematological patients[5,6]. The rate of severe *Candida* infections has rapidly increased in the last 15 years and has been a major concern in onco-hematology practice due to its poor prognosis in patients with neutropenia. Diagnosis of HSC is based on persistent fever under antibacterial therapy and a clinical suspicion of chronic disseminated candidiasis. Detection of yeast in the blood cultures has been helpful, but specific immunoserodiagnosis and PCR methods are other diagnostic procedures. Fluconazole and amphotericin B are first line drugs, however, if resistance is expected or patient has severe disease, a combination of liposomal amphotericin B and caspofungin, or voriconazole are also recommended for treatment of HSC and candidemia[7,8].

HSC diagnosis is based on clinical presentation, radiological modalities, microbiological procedures and histopathological examination. Early diagnosis of HSC or invasive candidiasis (IC) remains difficult as the clinical presentation is unspecific and blood cultures lack sensitivity and require long incubation times. Thus, non-culture-based methods have been developed. The Mannan antigen (Mn) and anti-mannan antibodies (A-Mn) have been shown to be effective for diagnosis[9]. In addition, fever, cough as well as diffuse reticulonodular opacities by CT can indicate invasive fungal infection. Due to persistent elevated ALP and GGT, abdominal MRI had been performed. It showed hepatosplenic hypodense masses that might be related to liver and spleen candidiasis or metastatic masses. Cancer screening tests were normal. Although remission of ATLL was achieved, liver lesions remained in MRI.

In a study conducted in Taiwan in 2002, HSC was diagnosed in 37 (7.4%) of the 500 adult patients with acute leukemia subsequent

to chemotherapy. Incidence rates of HSC were reported to be insignificant between patients with acute myeloid leukemia and those with acute lymphoblastic leukemia, and between the patients treated with high-dose chemotherapy and those with conventional or low-dose chemotherapy. *Candida tropicalis* was the most reported pathogen, followed by *Candida albicans*. CT was reported to show multiple hypodense lesions in the liver (89%), spleen (70%), and kidney (27%)[10]. Histologic confirmation of HSC can be considered by fine needle liver biopsy that cannot commonly be implemented.

Diagnosis was confirmed by non-invasive radiological modalities, serological tests that indicate the presence of circulating *Candida* antigens and invasive technique in our case. Caspofungin and voriconazole are recommended as some patient might be unresponsive to amphotericin B therapy. Treatment had been performed for three months with amphotericin B, caspofungin, and voriconazole, respectively[11,12].

If a patient with acute leukemia has persistent and unexplained fever under antibacterial treatment after recovering of neutropenia that develops subsequent to chemotherapy, HSC should be considered and examined. Fungal cultures may not yield a pathogen and diagnosis may depend on radiological findings. Antifungal treatment should be administered more than three months. Ongoing HSC treatment does not constitute a contraindication to chemotherapy to be administered.

Conflict of interest statement

We declare that we have no conflict of interest.

References

- [1] Sipsas NV, Lewis RE, Tarrand J, Hachem R, Roiston KV, Raad II, et al. Candidemia in patients with hematologic malignancies in the era of new antifungal agents (2001-2007): stable incidence but changing epidemiology of a still frequently lethal infection. *Cancer* 2009; **115**: 4745-52.
- [2] Jennane S, Eddou H, Mahtat EM, Konopacki J, Souleau B, Malfuson JV, et al. [Contribution of PET/CT for the management of hepatosplenic candidiasis in hematology]. *Med Mal Infect* 2014; **44**(6): 281-3. French.
- [3] Altintas A, Ayyildiz O, Isikdogan A, Atay E, Kaplan MA. Successful initial treatment with caspofungin alone for hepatosplenic candidiasis in a patient with acute myeloblastic leukemia. *Saudi Med J* 2006; **27**(9): 1423-4.
- [4] Teyton P, Baillet G, Hindié E, Filmont JE, Sarandi F, Toubert ME, et al. Hepatosplenic candidiasis imaged with F-18 FDG PET/CT. *Clin Nucl Med* 2009; **34**(7): 439-40.
- [5] Gedik H, Şimşek F, Kantürk A, Aydın D, Demirel N, Yokuş O, et al. When and which fungal pathogens should come to mind in patients with hematological malignancies? *Afr J Microbiol Res* 2013; **7**(9): 760-4.
- [6] Festekjian A, Neely M. Incidence and predictors of invasive candidiasis associated with candidaemia in children. *Mycoses* 2011; **54**(2): 146-53.
- [7] Gedik H, Şimşek F, Kantürk A, Yıldırım T, Arıca D, Aydın D, et al. Bloodstream infections in patients with hematological malignancies: which is more fatal—cancer or resistant pathogens? *Ther Clin Risk Manag* 2014; **10**: 743-53.
- [8] Poon LM, Chia HY, Tan LK, Liu TC, Koh LP. Successful intensive chemotherapy followed by autologous hematopoietic cell transplantation in a patient with acute myeloid leukemia and hepatosplenic candidiasis: case report and review of literature. *Transpl Infect Dis* 2009; **11**: 160-6.
- [9] Mikulska M, Calandra T, Sanguinetti M, Poulain D, Viscoli C, Third European Conference on Infections in Leukemia Group. The use of mannan antigen and anti-mannan antibodies in the diagnosis of invasive candidiasis: recommendations from the Third European Conference on Infections in Leukemia. *Crit Care* 2010; **14**(6): R222.
- [10] Chen CY, Chen YC, Tang JL, Yao M, Huang SY, Tsai W, et al. Hepatosplenic fungal infection in patients with acute leukemia in Taiwan: incidence, treatment, and prognosis. *Ann Hematol* 2003; **82**(2): 93-7.
- [11] Gedik H, Şimşek F, Yıldırım T, Kantürk A, Arıca D, Aydın D, et al. Primary or secondary antifungal prophylaxis in patients with hematological malignancies: efficacy and damage. *Ther Clin Risk Manag* 2014; **10**: 305-12.
- [12] Gedik H, Şimşek F, Yıldırım T, Kantürk A, Arıca D, Aydın D, et al. Novel antifungal drugs against fungal pathogens: do they provide promising results for treatment? *Indian J Hematol Blood Transfus* 2015; **31**(2): 196-205.